Essential Clinical Surface Anatomy

Dr. Marc Barton

Contents

Foreword

A solid knowledge of anatomy is at the core of many professions; including nursing, physiotherapy, the fitness and wellbeing industry, medicine and many others. It can be a daunting task to try and learn every aspect of the anatomical structure of the body, but the appreciation for the complexities of our bodies grows with our understanding.

Surface anatomy allows a clinician to recognize anatomical features that can be seen or felt without the need for dissection. From muscle insertions, to palpable arteries, bony prominences to organs in the abdomen – surface anatomy covers every system and area of the body. It is a fascinating subject, and is a prerequisite for anyone that looks after the human body in any way.

This book is an extremely helpful reference for anyone needing to grasp the essential facts of surface anatomy. Written by a true anatomical enthusiast, the body is divided into easily manageable sections with excellent clinical examples and references. It is simple and easy to read, and yet provides the reader with numerous facts from which they can further develop their knowledge base.

Dr. Clare Barton
MBBS, BSc(Hons), MRCGP, DRCOG

Introduction

Over the course of the 20 years or so that I have been involved in the field of Medicine, I have developed a guilty pleasure. That guilty pleasure is a love of anatomy. I have spent countless hours whilst preparing for exams exploring a variety of anatomy textbooks, but in my opinion nothing compares to the timeless splendor of the illustrations of the great anatomist Henry Vandyke Carter from Gray's Anatomy.

In the course of writing this book I have had the opportunity to spend many hours searching through the wealth of these beautiful anatomy images that are now available in the public domain and have included some of my very favourites to illustrate the most important surface anatomy landmarks. I hope that you enjoy them as much as I do. I would also like to thank the very talented Gareth Baxendale for his sterling work in providing several brand new images for this book.

This book is intended for use as a reference guide for healthcare professionals that can be easily accessed in a systems orientated manner. The information provided within will be found to be helpful in both medical examinations and in real life clinical practice.

A good knowledge of surface anatomy is an essential component of safe clinical practice. Surface anatomy is a descriptive science that allows healthcare professionals to indentify important anatomical landmarks structures without a need for invasive techniques. The important anatomical landmarks that it allows us to locate can be used for the purpose of proper and safe clinical examination, interpretation of investigations (e.g. CT scans and X-rays), and procedures and surgical techniques.

As I became a more experienced clinician the importance of a sound knowledge of surface anatomy became very evident. I have used my

experience of utilizing anatomical knowledge in the clinical setting to illustrate many key learning points.

I hope your journey learning anatomy is both enlightening and enjoyable.

Dr Marc Barton
BSc (Hons), MBBS, MRCP, MRCGP, MRCEM, DCH, DRCOG

1

Head and Neck

The Pterion and the Middle Meningeal Artery

The middle meningeal artery is usually the first branch of the first part of the maxillary artery, which itself is a branch of the external carotid artery. It is unique because it supplies some intracranial structures, whereas the other branches of the external carotid artery only supply extracranial structures.

The middle meningeal artery is clinically important because injury to it is the commonest cause of an epidural (extradural) haematoma.

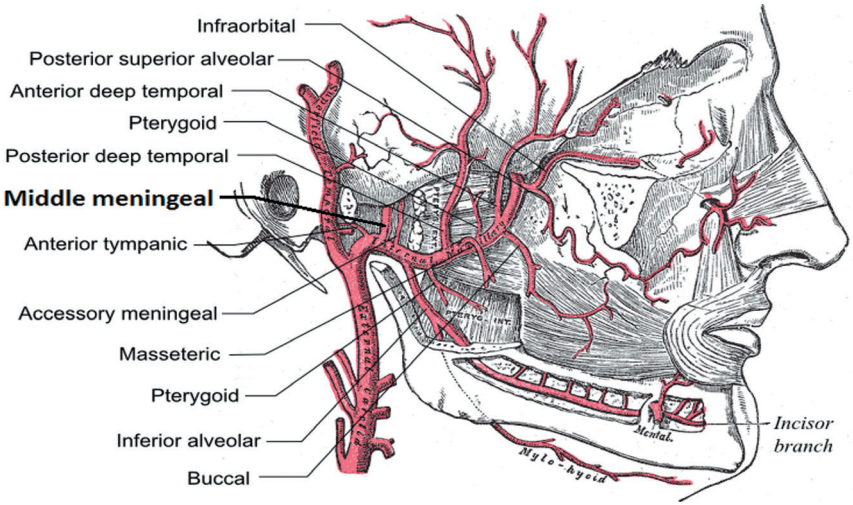

*Fig 1. The anatomical position and relations of the middle meningeal artery.**

The middle meningeal artery lies immediately beneath the pterion, which is the weakest part of the skull. A fracture of the skull here can injure or lacerate the middle meningeal artery causing an epidural haematoma to form.

The pterion can be located approximately 4 cm above the zygomatic arch and 3.5 cm behind the frontozygomatic suture.

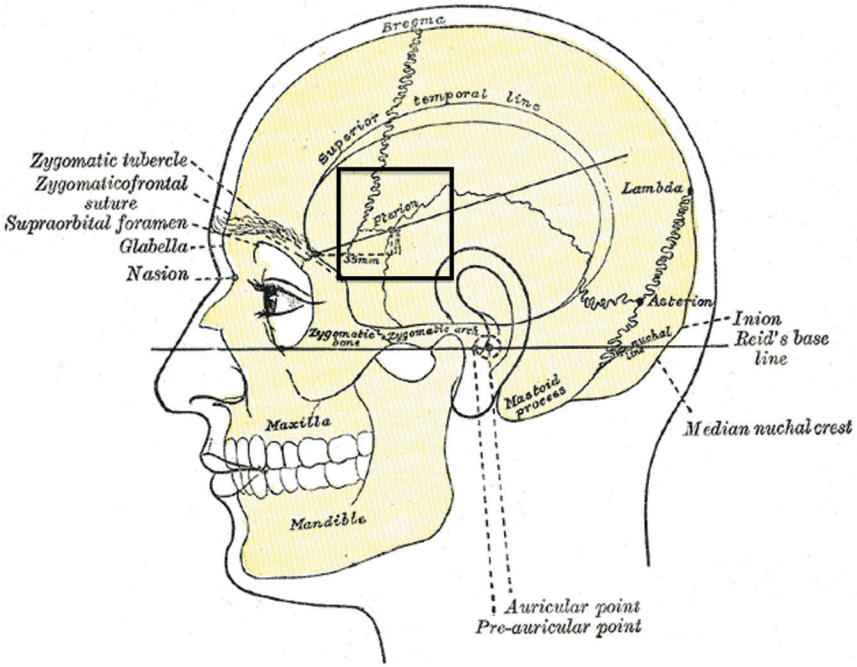

*Fig 2. The surface marking of the pterion.**

The Facial Artery

The facial artery is a branch of the external carotid artery that supplies the superficial structures of the face.

It follows a tortuous course across the face looping initially inferiorly and then upwards around the lower border of the mandible. **At**

this point it is easily palpable as it crosses the bone anterior to the insertion of the masseter muscle. It then runs in the superficial tissues of the face, ascending along the side of the nose, and then ending at the medial canthus of the eye.

The remarkably tortuous course of the facial artery serves to accommodate itself to the wide range of movements of the face and neck that can occur.

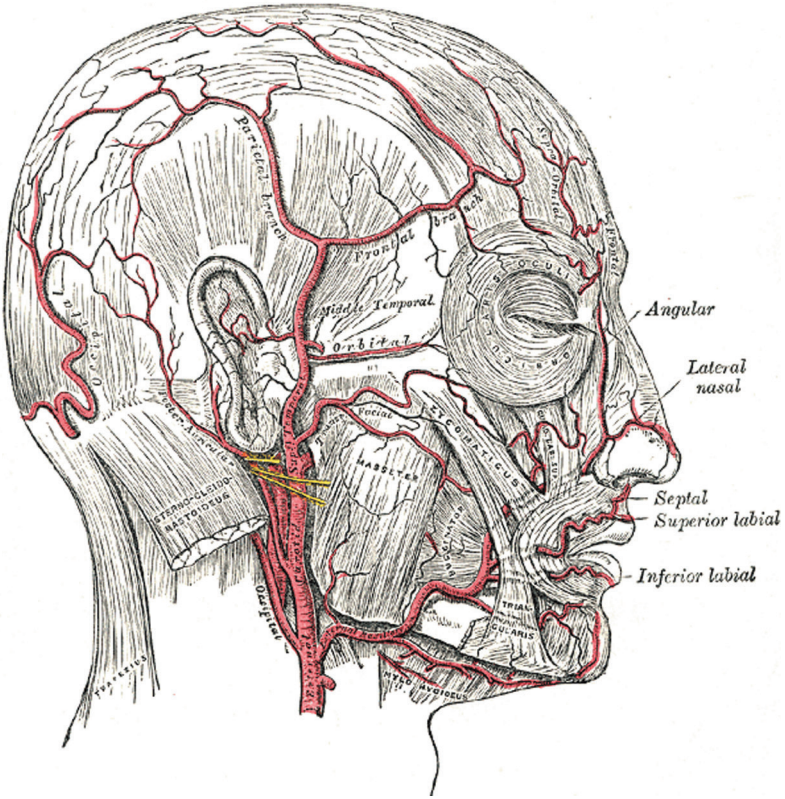

*Fig 3. The anatomical position and relations of the facial artery.**

The Superficial Temporal Artery

The superficial temporal artery is the smaller of the two terminal branches that bifurcate superiorly from the external carotid artery. It is clinically important as it is often affected in giant-cell arteritis and is biopsied if this diagnosis is suspected.

It begins in the substance of the parotid gland and passes superficially over the posterior part of the zygomatic process of the temporal bone. About 5 cm above this point it divides into its frontal and parietal branches.

The superficial temporal artery can be palpated just in front of the tragus of the ear.

The Subclavian Arteries

The subclavian arteries receive blood from the arch of the aorta and supply blood to the upper limbs. They also have branches that supply the head and thorax. The left subclavian artery arises directly from the arch of the aorta, whilst the right subclavian artery arises from the brachiocephalic artery.

The subclavian arteries can be palpated using deep pressure behind the middle of the clavicles.

The Common Carotid Arteries

The common carotid arteries receive blood from the arch of the aorta and supply blood to the head and neck. The left common carotid artery arises directly from the arch of the aorta, whilst the right common carotid artery arises from the brachiocephalic artery.

The common carotid arteries bifurcate into the external and internal carotid arteries at the level of the superior margin of the thyroid cartilage (C4). This bifurcation occurs in the anatomical area that is

referred to as the carotid triangle and it is here that the carotid sinus is located.

The common carotid artery in the neck can be located on a line that runs from the sternal end of the clavicle to a point mid-way between the tip of the mastoid process and the angle of the mandible. **The common carotid artery can be palpated in front of the sternocleidomastoid muscle along this line and can be compressed against the transverse process of the 6th cervical vertebra.**

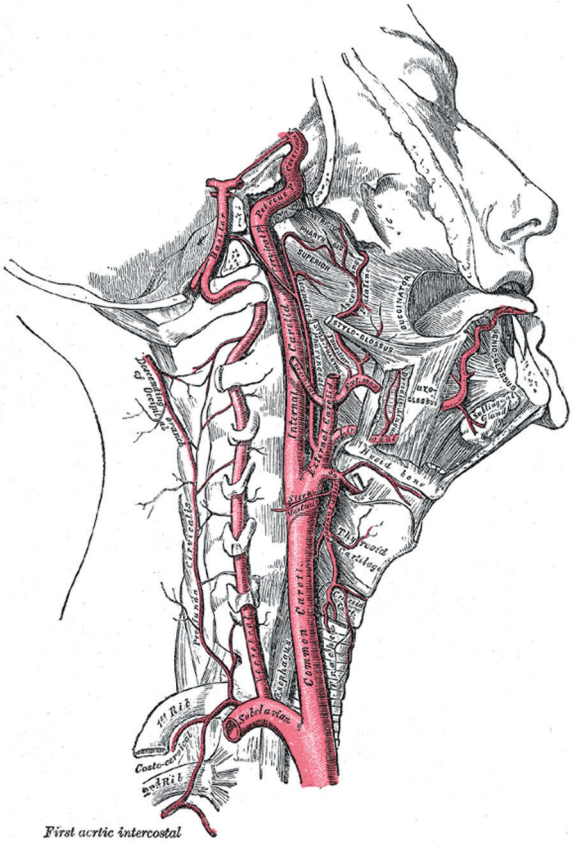

*Fig 4. The anatomical position and relations of the right common carotid artery.**

The Internal and External Jugular Veins

The external jugular vein is formed by the union of the retromandibular vein and the posterior auricular vein. These two veins unite posterior to the angle of the mandible and just inferior to the pinna. It is responsible for the drainage of the majority of the external face.

The terminal part of the external jugular vein can be located in the posterior triangle of the neck. It follows a course that roughly runs from the earlobe to the mid clavicle.

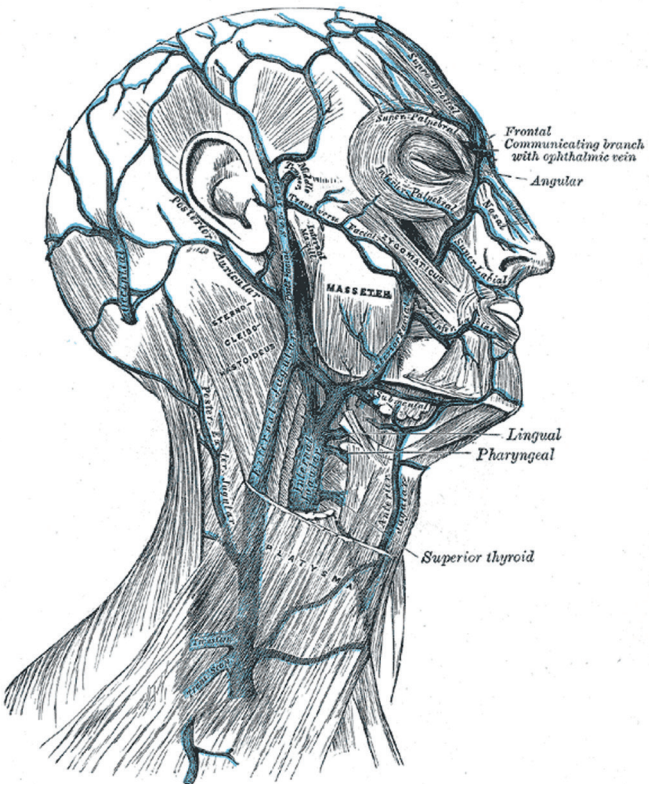

*Fig 5. The anatomical position and relations of the external and internal jugular veins.**

It is a large vein that is commonly used for venous access in the emergency setting. The vein is often difficult to see but can be distended by straining or pressure applied to the root of the neck.

The internal jugular vein is formed by the union of the inferior petrosal sinus and the sigmoid dural sinus in the posterior compartment of the jugular foramen. It runs in the carotid sheath with the vagus nerve and the common carotid artery. It combines with the subclavian vein to form the brachiocephalic vein at the bottom of the neck, posterior to the sternal end of the clavicle.

The internal jugular vein follows a course that roughly runs from the earlobe to the sternoclavicular joint.

The internal jugular vein is a large, central vein that is relatively superficial and for this reason it is commonly used for the placement of central venous catheters. The vein can be located by introducing a needle into the centre of a triangle that is formed by the two lower heads of the sternocleidomastoid muscle and the clavicle. The carotid artery should be palpated to ensure that the needle enters the skin lateral to the artery.

The other main clinical use of the internal jugular vein is for the observation of the jugular venous pressure (JVP). The JVP is the indirectly observed pressure. To properly observe the JVP the patient should be positioned at 45 degrees, with the right side of the neck generally preferred. The pulsation of the internal jugular vein can be seen between the two heads of sternocleidomastoid and can be a useful tool when attempting to differentiate between different types of cardiovascular and respiratory disease. Classically three upward deflections (the ‘a’, ‘c’, and ‘v’ waves) and two downward deflections (the ‘x’ and ‘y’ descents) are described. These correspond with different phases of the cardiac cycle.

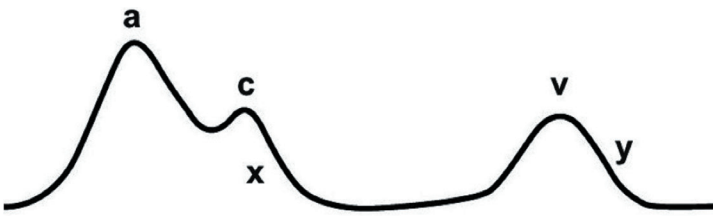

Fig 6. The components of the jugular venous pressure.

The components of the JVP are shown in the table below:

Waveform component	Phase of cardiac cycle	Mechanical event
a wave	End diastole	Atrial contraction
c wave	Early systole	Closing and bulging of the tricuspid valve
v wave	Late systole	Systolic filling of the atrium
x descent	Mid systole	Atrial relaxation
y descent	Early diastole	Early ventricular filling

The Supraorbital, Infraorbital, and Mental Nerves

The supraorbital nerve is a terminal branch of the frontal nerve. It supplies the upper eyelid, the frontal sinus and the skin of the forehead extending back to the middle of the scalp.

The infraorbital nerve is a branch of the maxillary nerve that is given off in the infraorbital canal. It supplies the lower eyelid, the upper lip, and part of nasal vestibule.

The mental nerve is a branch of the inferior alveolar nerve, which itself is a branch of the mandibular division of the trigeminal nerve. It supplies the anterior aspect of the chin and lower lip and buccal gingivae of the mandibular anterior teeth and the premolars.

Because of their superficial nature and relative ease of location, these nerves are frequently blocked with local anaesthesia in maxillofacial and dental surgery.

The supraorbital, infraorbital, and mental nerves can all be located on a vertical line that passes between the two premolar teeth upwards and dissects the pupil.

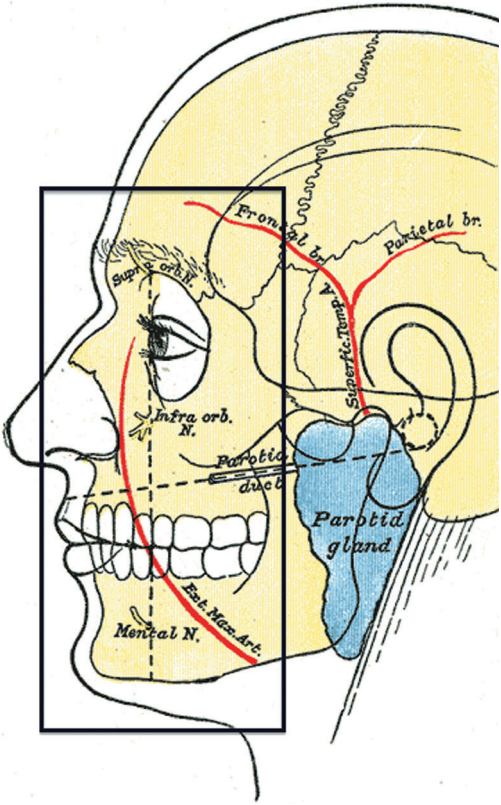

*Fig 7. The main surface markings of the face showing the vertical relationship of the supraorbital, infraorbital, and mental nerves.**

The Parotid Gland and Parotid Duct

The parotid gland is a large salivary gland that is located in the face. It is responsible for the production of serous saliva, a watery substance that is rich in enzymes and assists with the lubrication and digestion of food.

The parotid gland lies within a deep hollow that is referred to as the parotid region. The parotid region has the following boundaries:

- Superiorly – the zygomatic arch
- Inferiorly – the inferior border of the mandible
- Anteriorly – the masseter muscle
- Posteriorly – the external ear and sternocleidomastoid muscle

The parotid duct is situated centrally on a line that extends from the tragus of the ear to the middle of the upper lip. It can be palpated as it hooks over the anterior border of the masseter muscle.

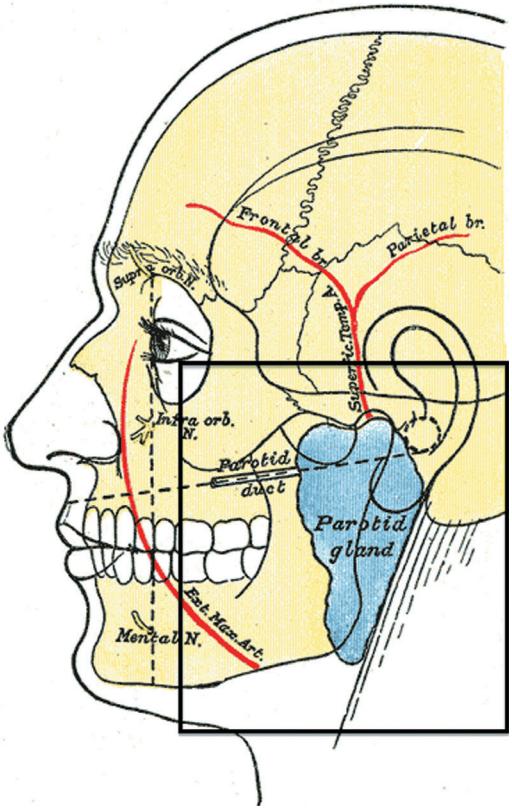

*Fig 8. The main surface markings of the face showing position of the parotid gland and the parotid duct.**

The anatomical relationships and surface markings of the parotid gland are of great importance, particularly in the setting of facial trauma and facial surgery. A number of important structures pass through the parotid gland and can be damaged in these scenarios. From lateral to medial, these are:

- The facial nerve (most lateral)
- Retromandibular vein
- External carotid artery
- Superficial temporal artery
- Branches of great auricular nerve
- Maxillary artery (most medial)

The Hyoid Bone and the Thyroid and Cricoid Cartilages

The hyoid bone and the thyroid and cricoid cartilages are all easily palpable anteriorly in the neck and are important anatomical landmarks.

The hyoid bone is a horseshoe shaped bone situated in the anterior midline of the neck between the chin and the thyroid cartilage. **It lies at the base of the mandible, approximately at the C3 vertebral level.** It is a site of attachment for several anterior neck muscles.

The thyroid cartilage is the largest of the nine cartilages that comprise the laryngeal skeleton. The superior edge of the thyroid cartilage is attached to the hyoid bone above by the thyrohyoid membrane**. The thyroid cartilage is located between the C4 and C5 vertebral levels.**

The cricoid cartilage is the only complete ring of cartilage around the trachea. It forms the posterior part of the larynx and functions as an attachment site for the muscles, cartilages, and ligaments that are involved in the production of speech and the opening and closing of the airway. **The cricoid cartilage is located immediately below the thyroid cartilage in the midline of the neck at the C6 vertebral level.**

The cricothyroid membrane is situated between cricoid and thyroid cartilages and is of significant clinical importance when establishing a surgical airway (e.g. cricothyroidotomy). When performing this procedure a 1 cm vertical incision is typically made through the overlying skin, followed by a horizontal incision through the cricothyroid membrane. An endotracheal tube or tracheostomy tube can then be inserted.

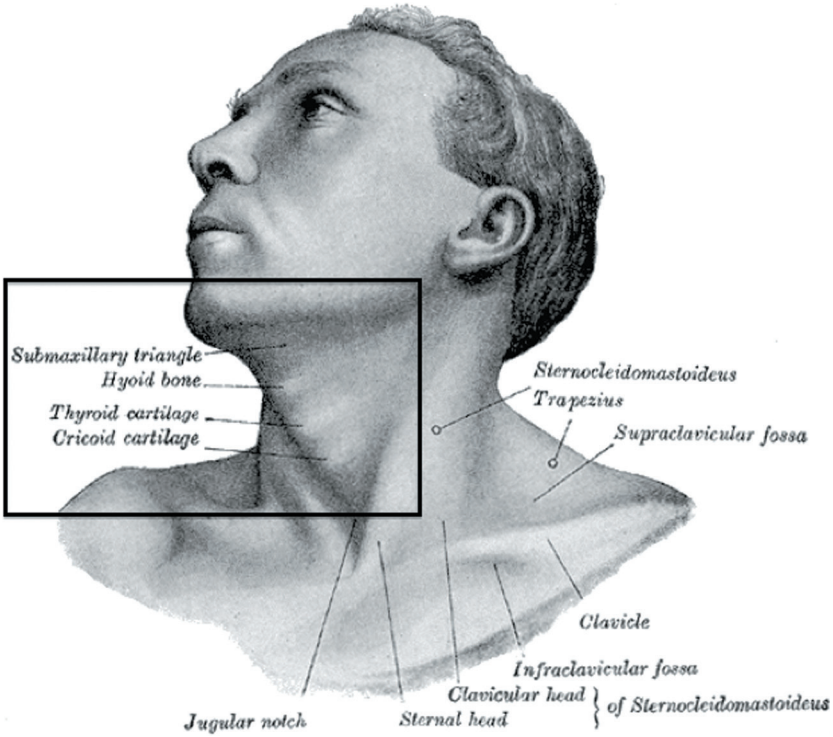

*Fig 9. The position of the hyoid bone and the thyroid and cricoid cartilages in the midline of the neck.**

The Triangles of the Neck

The triangles of the neck are useful in clinical medicine as a means of identifying the location of anatomical structures and

communicating the location of injuries, masses etc between healthcare professionals.

The anterior triangle of the neck is situated at the front of the neck in front of the sternocleidomastoid muscle. Its boundaries are as follows:

- Superiorly – the inferior border of the mandible
- Laterally – the anterior border of the sternocleidomastoid muscle
- Medially – the midline of the neck

The following structures are contained within the anterior triangle of the neck:

- Carotid sheath and branches of the external carotid artery
- Internal jugular, facial, retromandibular, external jugular and anterior jugular veins
- The ansa cervicalis, vagus nerve, hypoglossal nerve, and nerve to mylohyoid
- The hyoid bone, larynx, thyroid, parathyroid and oesophagus
- The submandibular gland
- Superficial cervical, submental, and buccal lymph nodes

The posterior triangle of the neck is situated on the lateral aspect of the neck behind the sternocleidomastoid muscle. Its boundaries are as follows:

- Anteriorly – the posterior border of the sternocleidomastoid muscle
- Posteriorly – the anterior border of the trapezius muscle
- Inferiorly – the middle third of the clavicle

The following structures are contained within the posterior triangle of the neck:

- The occipital, superficial cervical and suprascapular arteries
- The transverse cervical, suprascapular, and external jugular veins

- Branches of the cervical plexus and the spinal root of the accessory nerve
- The omohyoid muscle within its sling
- The occipital and supraclavicular lymph nodes

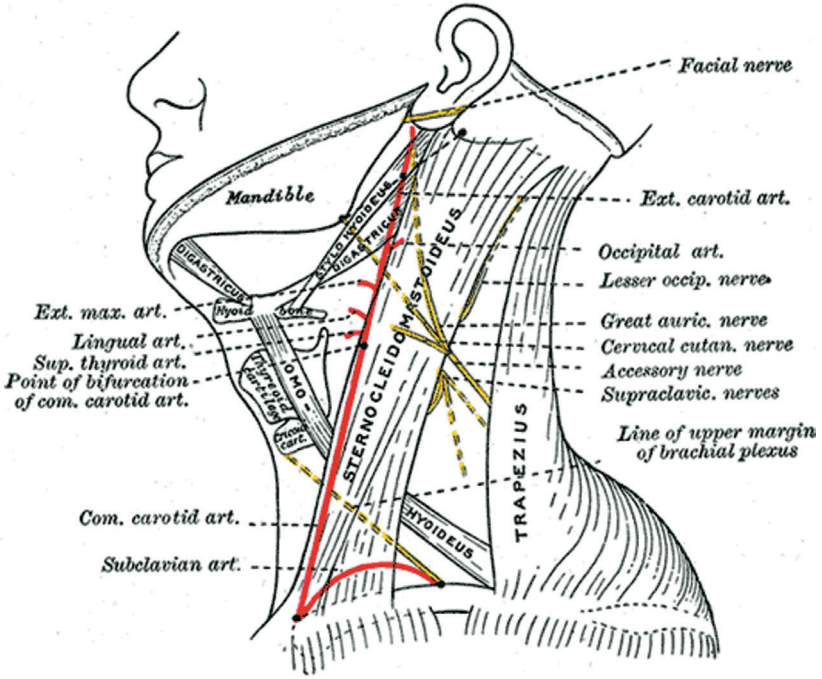

*Fig 10. The main surface markings within the triangles of the neck.**

The spinal root of the accessory nerve (CN XI) is relatively superficial and can be located within the posterior triangle of the neck and can be located approximately one third of the way down the posterior border of the sternocleidomastoid muscle.

2

Thorax

Lines of Orientation

There are several important imaginary lines that can be drawn on the thorax to enable easy description of locations of anatomical structures on the chest wall.

The mid-sternal line (anterior median line) line passes vertically through the centre of the sternum. It corresponds with the median plane that bisects the body vertically.

The mid-clavicular line runs parallel to the mid-sternal line and passes vertically through the midpoint of the clavicle.

The anterior axillary line passes vertically through the anterior axillary fold, close to the front of the thorax.

The posterior axillary line passes vertically through the posterior axillary fold, close to the back.

The mid-axillary line passes vertically through the midpoint between the anterior and posterior axillary lines.

The mid-vertebral line passes vertically through the midpoint of the vertebral column.

The scapular lines run parallel to the mid-vertebral line passing vertically through the inferior angles of the scapulae.

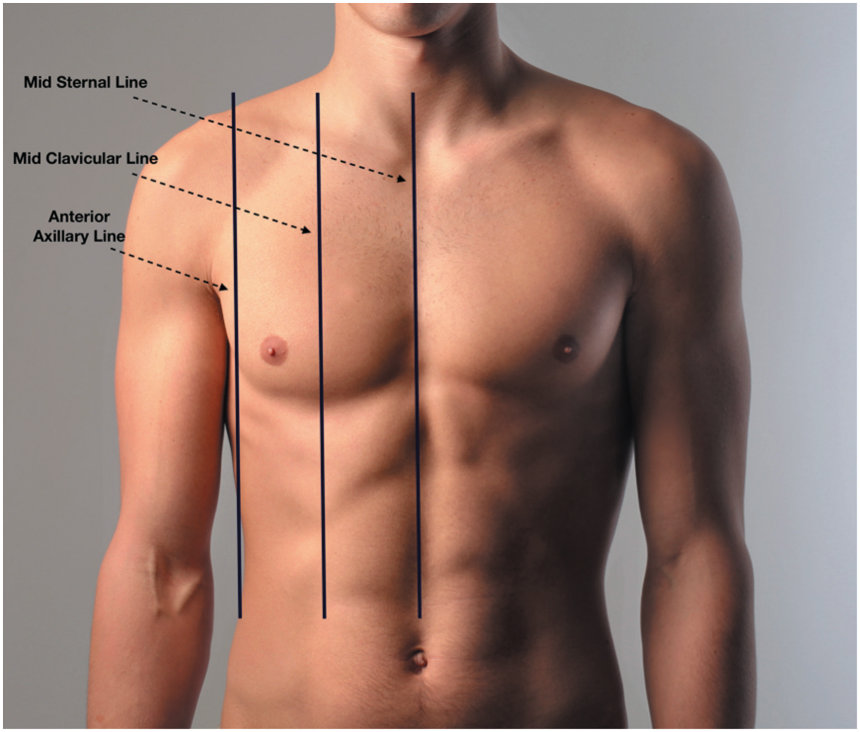

Fig 11. The lines of orientation on the anterior thorax.[§]

The Sternum

The sternum is the flat, elongated bone that forms the middle of the anterior part of the thoracic cage. It connects to the ribs via cartilage, forming the front of the rib cage, and helps to protect the heart, great vessels, and lungs from injury. It consists of three distinct parts:

1. **The manubrium:**
   This is a triangular shaped bone that lies at the T3/4 vertebral level. The superior border is indented by the suprasternal notch. Two clavicular notches lie on either side that articulate with the medial end of the clavicle. The 1st rib fuses with the lateral border just inferior to this.

2. **The body:**
   This is longer, narrower, and thinner than the manubrium and extends from the T5 to T9 vertebral levels. The body's nearly flat anterior surface is marked by three transverse ridges in the adult that represent the lines of fusion of its four originally separate segments.

3. **The xiphoid process:**
   This is the smallest and most variable part of the sternum. It is cartilaginous in young people but is usually fully ossified by 40 years of age.

The body connects with the manubrium via the manubriosternal joint. **Here the manubrium and the body lie in slightly different planes, forming the sternal angle, which lies at the T4/5 vertebral level. This readily palpable clinical landmark is located opposite the 2nd pair of costal cartilages.**

The suprasternal notch is situated in the midline superior to the upper edge of the manubrium between the medial ends of each clavicle.

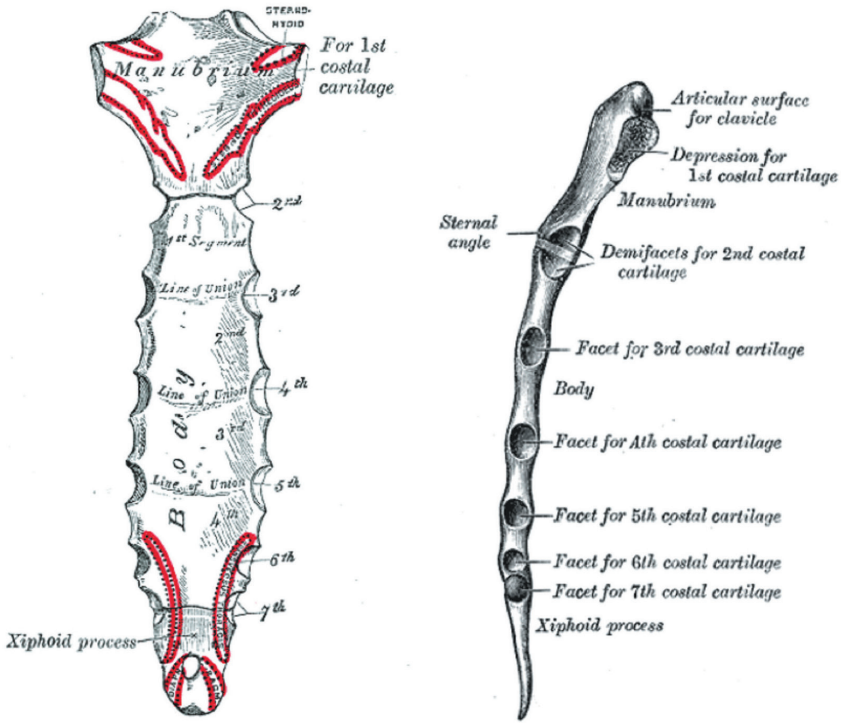

*Fig 12. The sternum and its relationship to the costal cartilages.**

The Spine and Spinal Cord

The most clearly palpable spinous process lies at C7, for this reason it has been given the name vertebra prominens. It has a long and prominent spinous process that is easily palpable from the skin surface.

The fourth lumbar vertebra (L4) lies at the level of the iliac crests and for this reason is a very useful landmark. This is the easiest lumbar vertebra to locate and can be used to count up and down the spinous processes to locate and number other vertebrae. Tuffier's line, also known as the intercristal line, is a theoretical line that joins the tops of the two iliac crests and passes through the 4th lumbar vertebra.

The spinal cord terminates at L1/2 in adults and L3 in infants. The subarachnoid space ends at S2 in adults and also lies lower in infants.

A good understanding and awareness of the location of the lumbar vertebrae and the point of termination of the spinal cord is vital when performing a lumbar puncture.

Although the cord usually terminates at L1/2, it is recognized as ending below this level in a significant proportion of patients. It is therefore recommended that a lumbar puncture (LP) should not be attempted above the L3/4 interspace. LPs can, however, be performed below this level in the L4/5 and L5/S1 interspaces.

When performing a lumbar puncture the patient should be placed either lying on their side or sitting with their back flexed. Back flexion opens the intervertebral spaces and therefore makes the procedure easier.

The CSF itself resides in the subarachnoid space between the pia mater and the arachnoid mater. In order to place the needle into the subarachnoid space, the needle passes between two vertebral processes and continues through the interspinal tissues and into the subarachnoid space. The spinal needle should be inserted in the midline and aimed slightly cranially.

The needle passes through the ligamentum flavum before entering the subarachnoid space. Resistance is felt to increase as the ligamentum flavum is entered and when the dura is encountered. A sudden 'give' is usually felt as the dura is pierced. Correct placement of the needle is confirmed by the appearance of CSF at the hub.

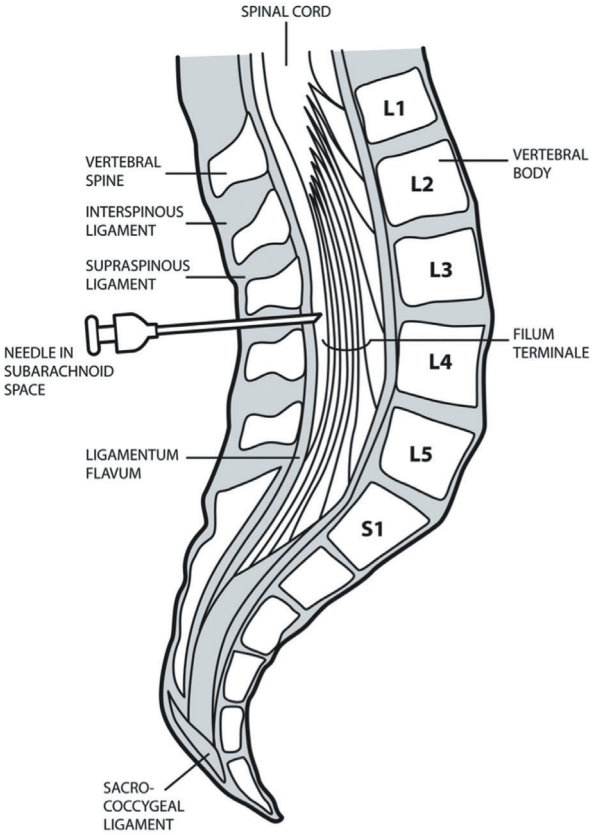

Fig 13. Lumbar puncture anatomy

The Trachea and Bronchi

The trachea is the first part of the tracheobronchial tree. It arises at the lower border of the cricoid cartilage at the C6 vertebral level and bifurcates to become the right and left main bronchi at the level of the sternal angle (T4/5). **The trachea can be easily palpated in the neck within the suprasternal notch.**

The left main bronchus is thinner but longer than the right. It is typically 5 cm long and enters the left lung opposite the 6th thoracic vertebra. The right main bronchus is wider, shorter and more vertical

than the left. It is typically 2.5 cm long and enters the right lung opposite the 5th thoracic vertebra.

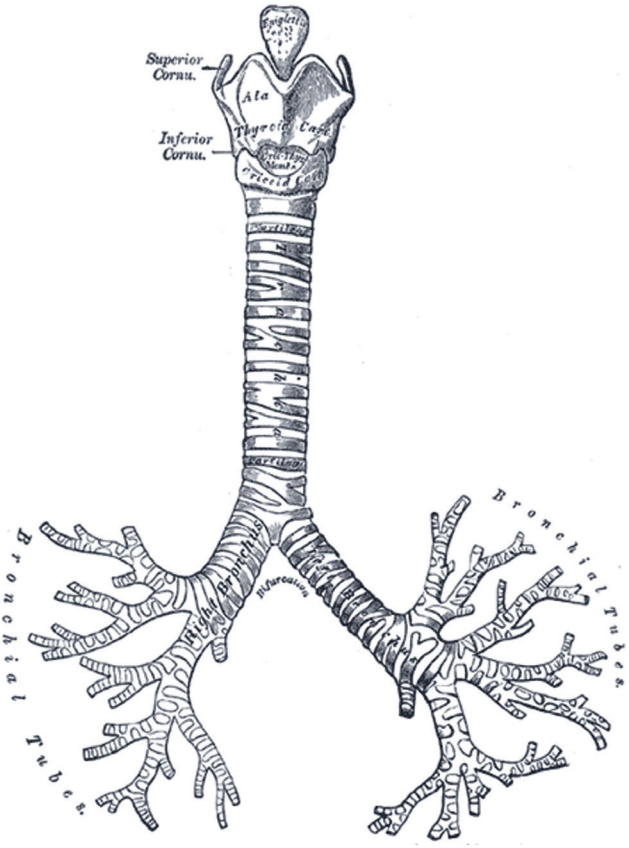

*Fig 14. The trachea and bronchi. **

The Lungs

The lungs are roughly cone shaped, with an apex, a base, three surfaces and three borders. The left lung is slightly smaller than the right due to the presence of the heart. The lobular structure of the lungs is different on the right and the left.

The right lung has three lobes, the superior, middle and inferior lobes. These are divided from each other by two fissures:

- The oblique fissure, which runs from the inferior border of the lung in a superoposterior direction, until it meets the posterior lung border
- The horizontal fissure, which runs from the sternum horizontally, at the level of the 4th rib, to meet the oblique fissure

The left lung contains two lobes, the superior and inferior lobes. These are divided by an oblique fissure, which runs from the inferior border of the lung in a superoposterior direction, in a similar manner to the oblique fissure on the right

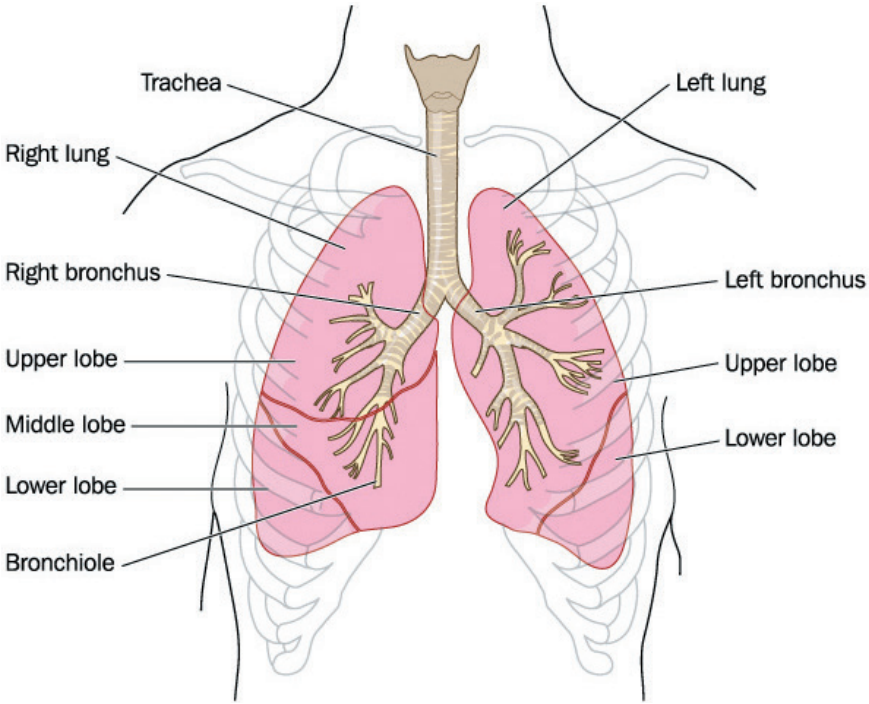

Fig 15. The lobes of the right and left lungs.[§]

The Pleura

The pulmonary pleurae are the two pleurae of the invaginated sac that surrounds each lung and attaches to the thoracic cavity. Each pleura can be divided into two parts:

- The parietal pleura, which covers the internal surface of the thoracic cavity and;
- The visceral pleura, which covers the lungs

The parietal and visceral pleura are continuous with each other at the hilum of each lung.

The apex of the pleura projects approximately 2.5 cm above the medial third of the clavicle. The lungs and pleurae are vulnerable to penetrating trauma at this point.

The pleurae then run down the sternum to the level of the 4th costal cartilage. The right pleura then passes downwards to the level of the 6th costal cartilage. The left pleura passes laterally first at the level of the 4th costal cartilage and descends lateral to the sternum to the level of the 6th costal cartilage. From here the pleurae pass posteriorly across the 8th rib at the mid-clavicular line, the 10th rib in the mid-axillary line before finally reaching the level of the 12th rib.

A pleural effusion is excess fluid that accumulates in the pleural cavity; the fluid filled space that is situated between the parietal and visceral pleura. The pleural cavity usually contains between 5-10 ml of this lubricating fluid. This fluid lubricates the surfaces of the pleurae, allowing them to slide over each other. It also produces a surface tension that pulls the two membranes together and ensures that as the thorax expands, the lungs do also and fill with air. Excess fluid in the pleural cavity impairs breathing by limiting expansion of the lungs.

Percutaneous pleural aspiration is generally carried out for two main indications:

1. For investigation of pleural effusion
2. For symptomatic relief of breathlessness caused by pleural effusion

The British Thoracic Society (BTS) guidelines suggest that pleural aspiration should be reserved for the investigation of unilateral exudative pleural effusions. It should not be carried out if unilateral or bilateral transudative effusion is suspected, unless there are atypical features or failure of response to therapy. It can also be used for the urgent decompression of the pleural space for the relief of respiratory distress caused by pleural effusion.

The procedure is usually carried out with the patient sat upright with a pillow used to support their arms and head. The patient should not lean forwards too much as it increases the risk of injury to the liver and spleen.

The conventional site for aspiration is posteriorly in the mid-scapular line (approximately 10 cm lateral to the spine), one or two spaces below the upper level of the fluid. The needle should be inserted just above the upper border of the chosen rib to avoid the intercostal nerves and vessels that run immediately below the rib.

The Heart

In a typical anatomical orientation, the heart has five surfaces, formed by different internal divisions of the heart:

- Anterior surface – right ventricle
- Posterior surface – left atrium
- Inferior surface – left and right ventricles
- Right pulmonary surface – right atrium
- Left pulmonary surface – left ventricle

The surfaces of the heart are separated by its borders. The four main borders of the heart are formed by the following:

- Superior border – right and left atrium (and the great vessels)
- Inferior border – left and right ventricles
- Right border – right atrium
- Left border – mainly the left ventricle (plus some of the left atrium)

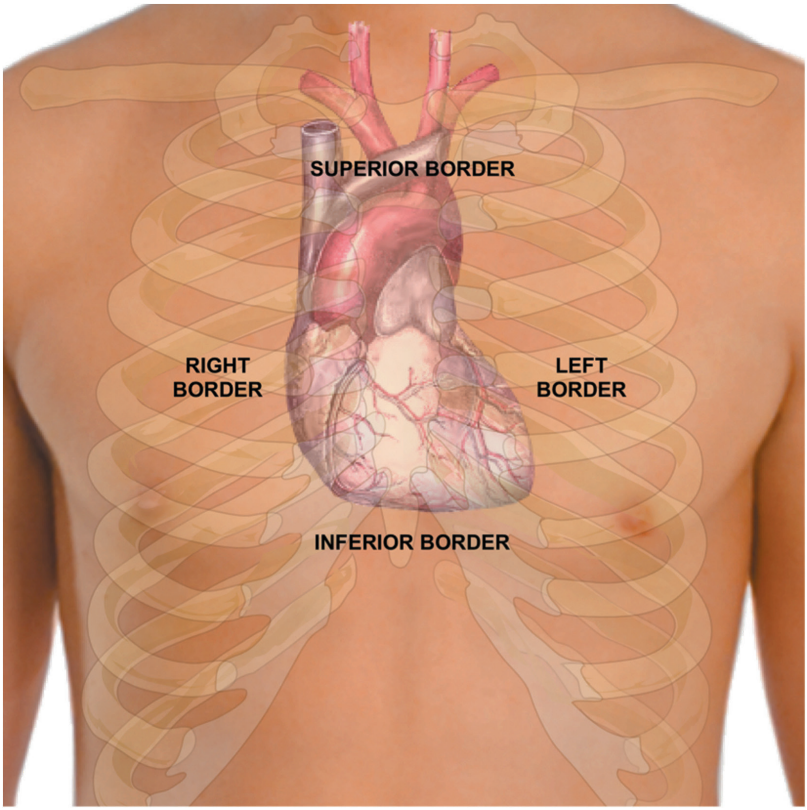

Fig 16. The four main borders of the heart.

The surface markings of the four heart valves do not exactly correspond with their auscultatory areas. Instead the auscultatory areas are where the sounds are transmitted and heard best.

The following table describes the surface marking and auscultatory areas of the four heart valves:

Valve	Surface Marking	Auscultatory Area
Pulmonary valve	Upper border of sternal end of left 3rd costal cartilage	Left 2nd intercostal space near sternum
Aortic valve	Lower border of sternal end of left 3rd costal cartilage	Right 2nd intercostal space near sternum
Mitral valve	Sternal end of left 4th costal cartilage	Cardiac apex (medial to mid-clavicular line in left 5th intercostal space)
Tricuspid valve	Right half of sternum along 4th and 5th intercostal spaces	Right lower end of sternum

The Great Vessels

The aortic arch commences at the point of the pericardial reflection on the aorta, which is posterior to the manubriosternal joint at the level of the second costal cartilage. It passes posterior and to the left, over the left main bronchus and ends at the left side of the body of the 4th thoracic vertebra.

Its highest level is the mid point of the manubrium sterni and it is at this level that its three main branches arise:

1. Brachiocephalic artery, which supplies blood to the brain, head, and right side of the thorax
2. Left common carotid artery, which supplies blood to the left side of the head and neck
3. Left subclavian artery, which supplies blood to the left side of the thorax

The descending aorta commences at the end of the arch of the aorta, which is at the level of the intervertebral disc between the 4th and 5th thoracic vertebrae. The descending aorta, in turn, becomes the thoracic and abdominal aorta.

The superior vena cava is formed by the right and left brachiocephalic veins at the right border of the sternum between the 2nd and 3rd costal cartilages.

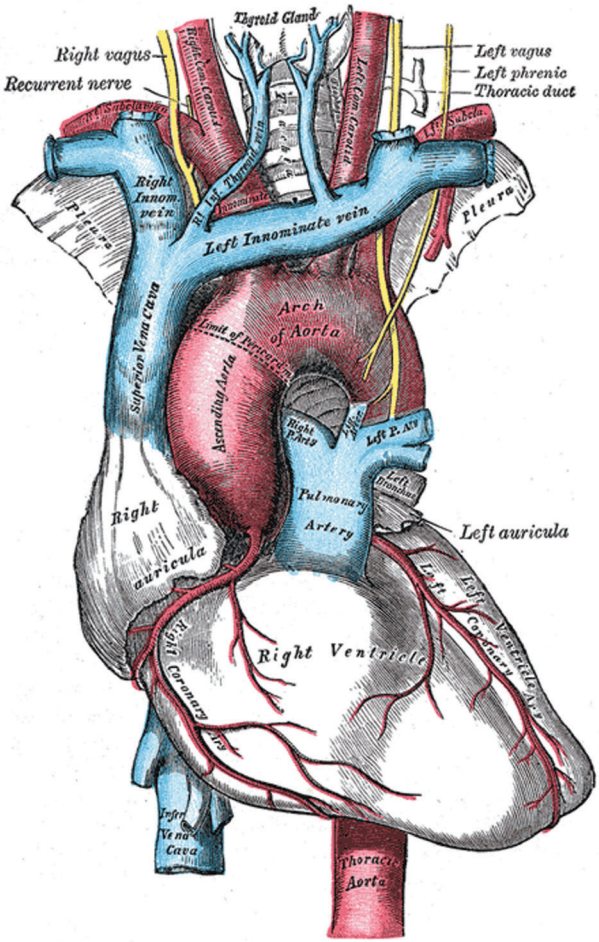

*Fig 17. The heart and great vessels. **

The Diaphragm

The diaphragm is a double-domed sheet of muscle that is situated at the lowest aspect of the rib cage. It serves to separate the thoracic cavity from the abdominal cavity and assists with inspiration and expiration.

In mid-inspiration the top of the right dome of the diaphragm reaches the upper border of the 5th rib in the mid-clavicular line. The left dome does not extend quite as high and only reaches the lower border of the 5th rib.

The diaphragm has three main openings:

- The caval opening: passes through the central tendon
- The oesophageal hiatus: situated in the posterior part of the diaphragm, to the left of the central tendon through the muscular sling of the right crus
- The aortic hiatus: situated in the posterior part of the diaphragm, between the left and right crus

The main openings in the diaphragm and their contents are shown in the table below:

Opening	Vertebral level	Contents
Caval opening	T8	Inferior vena cava Branches of right phrenic nerve
Oesophageal hiatus	T10	Oesophagus Anterior vagal trunk Posterior vagal trunk Oesophageal branches of left gastric vessels
Aortic hiatus	T12	Aorta Azygous veins Thoracic duct

Placement of ECG Electrodes

A good understanding of the surface anatomy of the thorax is essential when placing ECG electrodes on the chest wall. The correct placement of electrodes is vitally important as misplacement can result in misinterpretation and missed or incorrect diagnosis. Somewhat confusingly a 12-lead ECG only has 10 electrodes. These 10 electrodes allow the electrical activity of the heart to be looked at from 12 different positions. There are 4 limb electrodes and 6 chest electrodes and their placement is as follows:

Chest electrodes:

- V1 – Right sternal edge, 4th intercostal space
- V2 – Left sternal edge, 4th intercostal space
- V3 – Midway between V2 and V4
- V4 – Left midclavicular line, 5th intercostal space
- V5 – Anterior axillary line, 5th intercostal space
- V6 – Left midaxillary line, 5th intercostal space

Limb electrodes:

- LA – Left arm (between shoulder and elbow)
- RA – Right arm (between shoulder and elbow)
- LL – Left leg (above the ankle and below the torso)
- RL – Right leg (above the ankle and below the torso)

The lead attached to the right leg is a neutral lead and is solely present to complete the electrical circuit. It plays no role in the formation of the ECG itself.

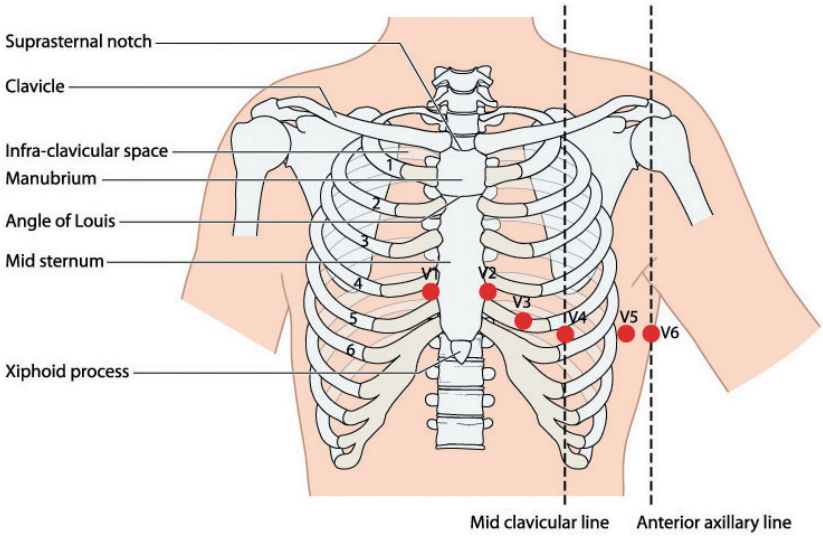

Fig 18. The placement of ECG electrodes.[§]

Tension Pneumothorax

A pneumothorax is the abnormal collection of air within the pleural space that exists between the visceral and parietal pleura. A tension pneumothorax occurs when a "one-way" air leak occurs from the lung. Air is forced into the pleural space but has no means of escape. Untreated this will cause complete collapse of the affected lung and eventually will displace the mediastinum, compress the great vessels and reduce cardiac output resulting in obstructive shock and death.

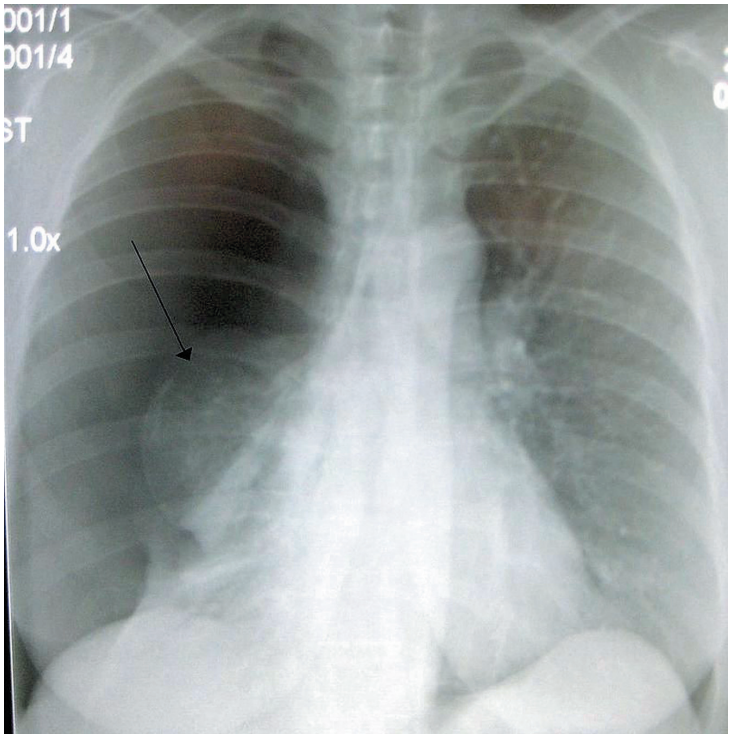

Fig 19. X-ray demonstrating a right-sided pneumothorax.

Tension pneumothorax requires immediate treatment with needle decompression. **This is performed by the insertion of a large-bore needle into the second intercostal space of the mid-clavicular line on the affected side.**

The definitive treatment of a tension pneumothorax is the insertion of a chest drain. **The optimal position for insertion of a chest drain is in the 5th intercostal space in the mid-axillary line (or just anterior to the mid-axillary line).** The neurovascular bundle lies high in the intercostal space, therefore the intercostal space should be penetrated as low as possible (close to the rib below) during chest drain insertion.

Thoracotomy

An anterolateral thoracotomy is performed on the anterior chest wall. It is the accepted approach for Emergency Department thoracotomy and a left-sided approach is used in all patients in traumatic arrest and also in those with left-sided chest injuries. In patients that have not arrested but have profound hypotension and right-sided chest injuries a right-sided approach should be used.

The procedure is carried out as follows:

- An incision is made along the 4th or 5th intercostal space from the sternum anteriorly to the posterior axillary line
- The incision should be deep enough to partially transect the latissimus dorsi muscle
- The skin, subcutaneous fat, and the superficial portions of the pectoralis and serratus muscles are divided
- The parietal pleura is divided and the pleural cavity is entered
- The intercostal muscles are then completely transected, a rib spreader placed and then opened to allow visualization of the thoracic cavity

The anterolateral approach permits access to most of the important anatomical structures during resuscitation, including the pulmonary hilum, heart and the aorta.

If an injury to the right side of the heart is suspected, another incision can be made on the right, extending it across the entire chest. This is referred to as a bilateral anterolateral thoracotomy, or a clamshell thoracotomy.

3

Abdomen and Pelvis

Lines of Orientation

The abdomen has fewer prominent anatomical landmarks than the thorax, and is broken up only by the costal margins, anterior and superior iliac spines, and the umbilicus.

The simplest and most widely used system of dividing the abdomen into regions is the division of the abdomen into four quadrants. This is done by drawing a vertical and horizontal line through the umbilicus to form the right and left upper and lower quadrants.

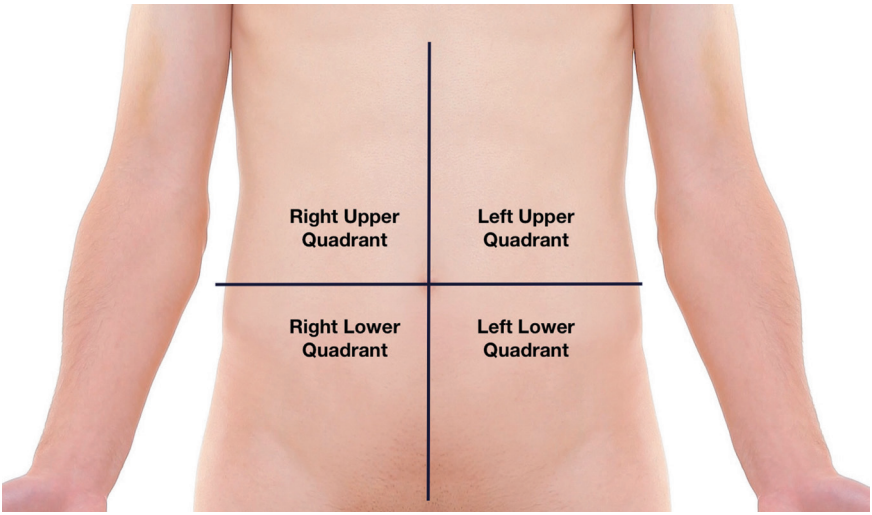

Fig 20. The division of the abdomen into quadrants.

The abdomen can also be divided using two imaginary lines that pass vertically through a point halfway between the anterior superior iliac spine and the pubic tubercle.

Two further lines can be added, the transpyloric plane of Addison and the transtubercular plane. These permit the subdivision of the abdomen into nine regions:

- Right and left hypochondriae
- Right and left lumbar areas
- Right and left iliac fossae
- Epigastric area
- Umbilical area
- Hypogastric area

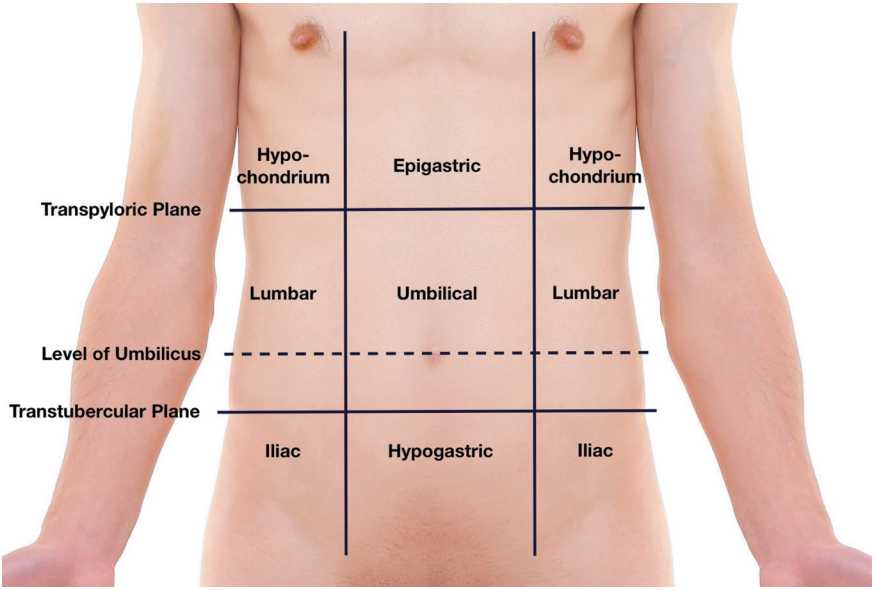

Fig 21. The lines of orientation on the abdomen.

The transpyloric plane of Addison crosses the L1 vertebral level. It is notable because it passes through several important abdominal structures including the following:

- The fundus of the gallbladder
- The hila of the kidneys
- The first part of the duodenum
- The neck of the pancreas
- The origin of the superior mesenteric artery
- The origin of the portal vein
- The pylorus of the stomach
- The hilum of the spleen
- The cisterna chyli
- The end of the spinal cord (L1/2)

The transtubercular plane corresponds to a line that passes through the tubercles of the iliac crests and lies at the L4 vertebral level.

The costal margin marks the lower margin of the thorax and demarcates the start of the abdomen. It is formed by the costal cartilages anteriorly, the 7th to 10th ribs laterally, and the 11th and 12th ribs posteriorly.

The linea alba is a fibrous structure that runs down the midline in the median plane from the xiphoid process to the pubic symphysis. It is formed by the fusion of the aponeurosis of the muscles of the anterior abdominal wall.

The pubic symphysis is the midline cartilaginous joint that unites the superior rami of the left and right pubic bones. It is easily palpable and serves as a very useful anatomical landmark.

The Stomach

The stomach is a J-shaped digestive organ that lies in the superior aspect of the abdomen between the oesophagus and the duodenum. Its position is in constant flux depending upon the phase of gastric digestion and the amount and character of its contents. For that reason it is impossible to be fully accurate when estimating its position.

When moderately filled with the patient in the supine position:

- The cardiac orifice lies opposite the left 7th costal cartilage approximately 2.5 cm lateral to the sternum (T10)
- The pyloric orifice lies on the transpyloric plane of Addison approximately 1 cm to the right of the midline

The stomach has four main regions:

- The cardia – which is around the opening of the oesophagus
- The fundus – which is the dilated superior portion lying beneath the left dome of the diaphragm
- The body – which is the large central position lying between the fundus and the pylorus
- The pylorus – which is the lower portion that facilitates the emptying of its contents into the duodenum

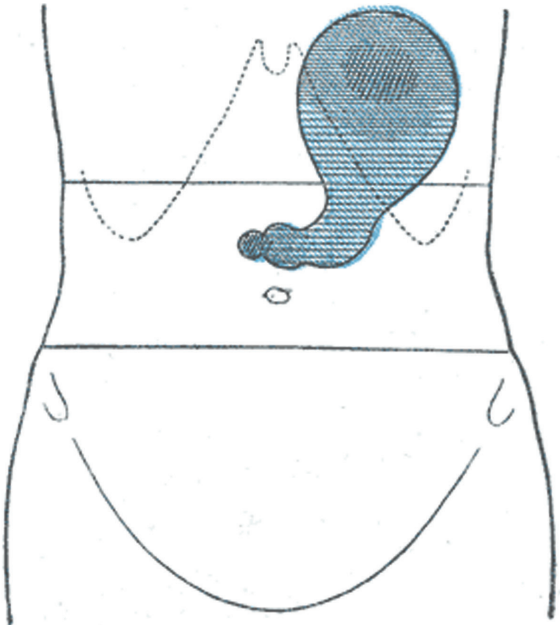

*Fig 22. The surface marking of a moderately full stomach in the supine position. **

The Duodenum

The duodenum is the shortest, widest and most proximal part of the small intestine. It commences at the pylorus on the right side and extends to the duodenojejunal junction on the left side. Between these two points it pursues a 'C-shaped' course around the head of the pancreas.

The duodenum can be divided into four parts:

1. **The superior (first) part:**
   This superior part is short (around 5 cm long) and lies anterior to the body of L1. The first 2 cm is mobile and is referred to as the duodenal cap. Duodenal ulcers are most likely to occur in this part of the duodenum.

2. **The descending (second) part:**
   This is the longest part (around 7-10 cm long) and descends along the right side of the L1-L3 vertebrae. This part curves inferiorly around the head of the pancreas.

3. **The inferior (third) part:**
   This part is around 6-8 cm long and passes laterally to the left, crossing the body of L3.

4. **The ascending (fourth) part:**
   The ascending part is short (around 5 cm long). It begins to the left of L3 and ascends to the level of the superior border of L2. During its ascent it curves anteriorly at a sharp turn referred to as the duodenojejunal flexure.

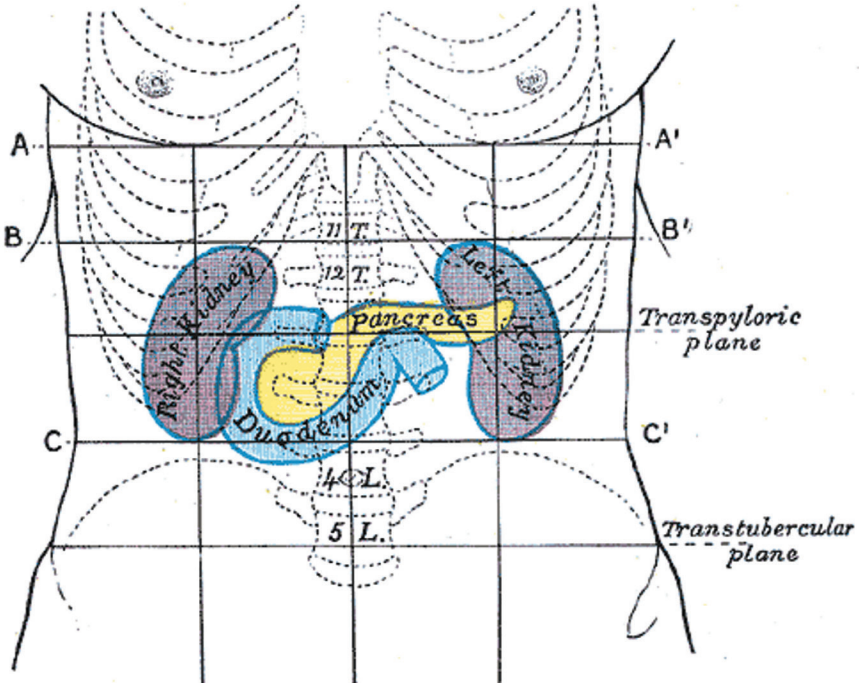

*Fig 23. The surface marking of the duodenum (in blue). **

The Jejunum and Ileum

The jejunum is the second part of the small intestine and lies between the duodenum and the ileum. It begins at the attachment of the suspensory muscle of the duodenum, which is located at the duodenojejunal flexure.

The ileum is the third and final part of the small intestine and lies between the duodenum and the ileum. It continues from the jejunum but there is no clear external demarcation between the two. The ileum ends at the ileocaecal junction, where the ileum invaginates into the caecum to form the ileocaecal valve.

A Meckel's diverticulum is a vestigial remnant of the vitellointestinal duct. It is the commonest malformation of the gastrointestinal tract,

being present in around 2% of the population. They are twice as common in men than women.

When present, a Meckel's diverticulum is located in the distal ileum, usually within 60-100 cm (2 feet) of the ileocaecal valve. They are usually 3-6 cm (approx. 2 inches) long and may have a greater lumen than that of the ileum.

They are commonly found as an incidental finding, particularly at appendicectomy. The majority are asymptomatic but they can present with the following complications:

- Haemorrhage (25-50% of complications)
- Intestinal obstruction (10-40% of complications)
- Diverticulitis
- Perforation

The '**rule of 2s**' is a useful aide-mémoire for remembering key facts about Meckel's diverticulum:

- 2% of the population
- 2:1 male: female ratio
- 2 feet from the ileocaecal valve
- 2 inches in length
- 2 types of common ectopic tissue (gastric and pancreatic)
- 2 years most common age at clinical presentation

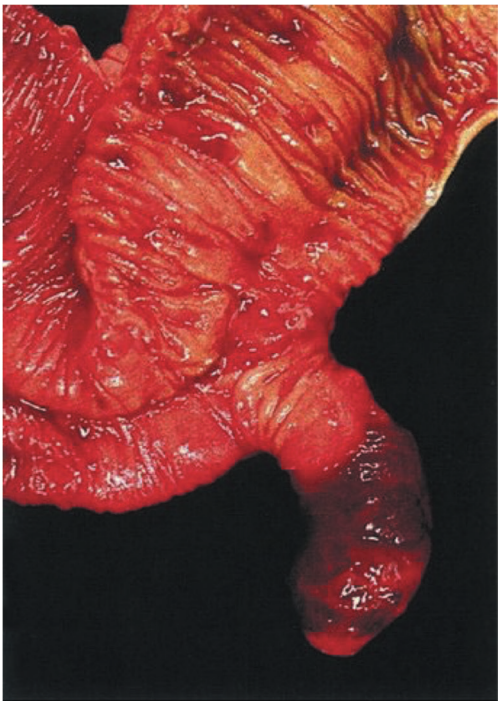

Fig 24. Surgical specimen of a Meckel's diverticulum.

The Caecum and Appendix

The caecum is the most proximal part of the large intestine and is located between the ileum and the ascending colon. It acts as a reservoir for chyme received from the ileum.

The caecum is located just inferior to the ileocaecal junction within the right iliac fossa and can be palpated here if enlarged.

The appendix is a narrow, worm-shaped, blind-ended tube that is attached to the posteromedial end of the caecum. It contains a large quantity of lymphoid tissue but serves no important function in humans. The position of the free-end of the appendix is highly variable.

There are five main locations at which it can be found, the two commonest being the retrocaecal and subcaecal positions. The distribution of positions is as follows:

- Ascending retrocaecal (64%)
- Subcaecal (32%)
- Transverse retrocaecal (2%)
- Ascending preileal (1%)
- Ascending retroileal (0.5%)

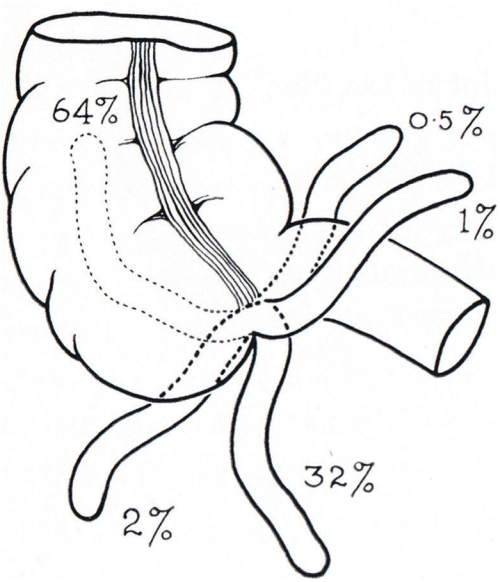

Fig 25. Distribution of the position of the appendix tip.[†]

Appendicitis is acute inflammation of the appendix and is one of the most common causes of the acute abdomen. It is typically a disease of children and young adults with a peak incidence in the 2nd to 3rd decades of life.

The classical presentation of appendicitis is with poorly localized periumbilical pain (referred pain from the visceral peritoneum). Within a day or two this pain typically localizes to McBurney's point

(pain from parietal peritoneum). There is usually associated fever, anorexia and nausea.

McBurney's point is defined as being the point that lies one-third of the distance from the anterior superior iliac spine to the umbilicus. It roughly corresponds with the most common position of the attachment of the base of the appendix to the caecum.

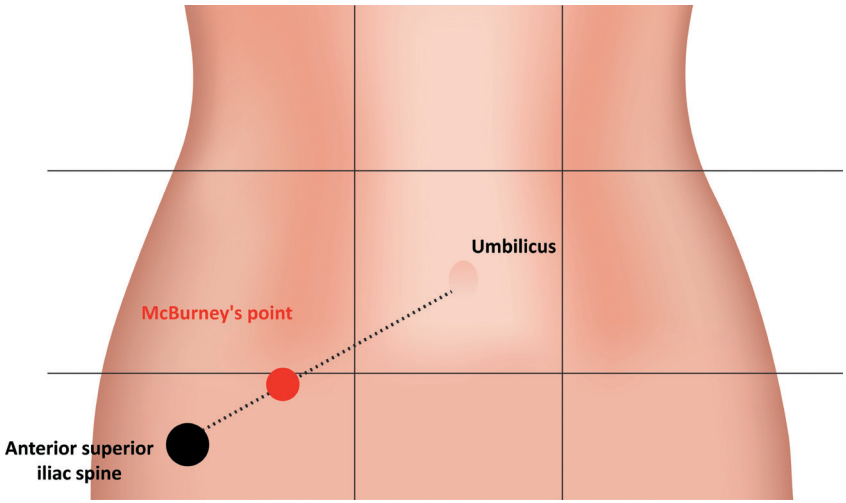

Fig 26. The anatomical position of McBurney's Point.[§]

The Colon

The colon is the part of the large intestine that is situated between the caecum and the rectum. It receives digested food from the small intestine, from which it absorbs water and ions to form faeces. It is approximately 150 cm in length and is divided into four parts:

1. **Ascending colon:**
   This is the first part of the colon and is retroperitoneal. It ascends upwards from the caecum before turning right at a 90 degree angle at the right colic flexure (hepatic flexure) to become the transverse colon. It is approximately 20 cm long.

2. **Transverse colon:**
   This is the second part of the colon and is intraperitoneal. It extends transversely across the abdomen from the right colic flexure until it reaches the left colic flexure (splenic flexure) close to the spleen. Here it turns another 90 degrees inferiorly to become the descending colon. The transverse colon is the least fixed part of the colon. It is approximately 50 cm long.

3. **Descending colon:**
   This is the third part of the colon and is retroperitoneal in the majority of people. It extends inferiorly down the abdomen from the left colic flexure passing over the lateral border of the left kidney. At the point that it turns medially it becomes the sigmoid colon. It is approximately 30 cm long.

4. **Sigmoid colon:**
   This is the final part of the colon and is intraperitoneal. It extends downwards in an 'S' shape from the left iliac fossa to the level of the S3 vertebra. It is approximately 50 cm long.

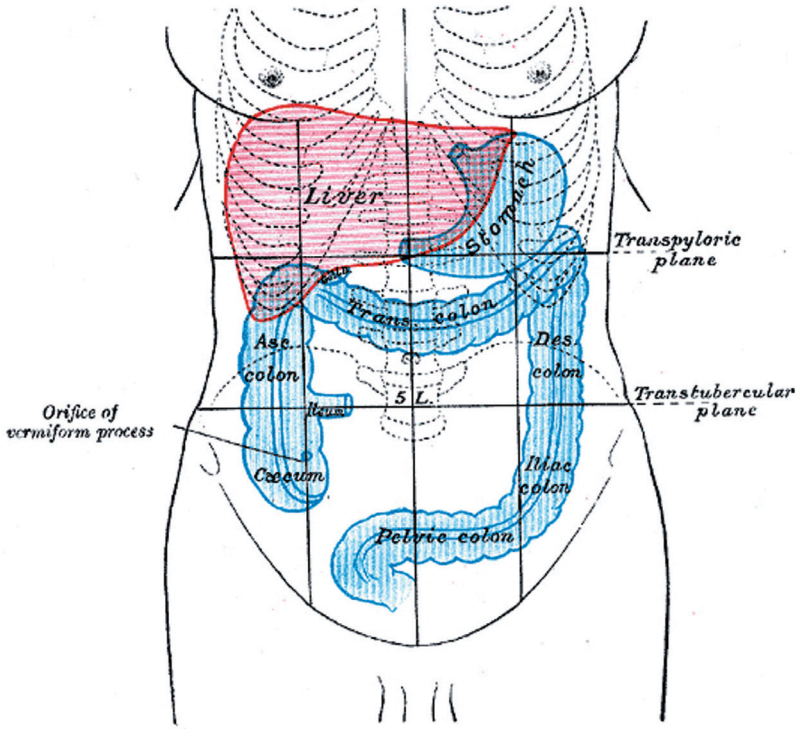

*Fig 27. The surface marking of the colon (in blue) and the liver (in red). **

The Rectum and Anal Canal

The rectum is the most distal segment of the large intestine and is located in the pelvic cavity. **It is approximately 12-15 cm long and commences at the recto sigmoid junction at the S3 vertebral level.**

The rectum ends at the anorectal junction, which is the level that the puborectalis sling is located, which is formed by the puborectalis muscle.

The anal canal is the final 4 cm of the alimentary tract and extends from the anorectal junction, inferoposteriorly to the anus.

The Liver

The liver is triangular in shape when viewed anteriorly. It is mainly situated underneath the right dome of the diaphragm, deep to the lower thoracic wall, protected by the thoracic cage. **The inferior margin can be easily palpated below the right costal margin when the patient inhales deeply because of the inferior movement of the diaphragm and liver.**

The following are useful surface markings:

- The upper border of the liver lies at the T6 vertebral level
- The left lobe of the liver lies just to the left of the midline
- The lower limit of the liver at the midline is approximately 3 cm below the xiphoid process
- Normally it extends inferiorly as far as the right costal margin

The liver has three hepatic recesses, which are spaces situated between itself and surrounding structures:

- The left and right subphrenic recesses – between the liver and diaphragm on either side of the falciform ligament
- The hepatorenal recess (Morison's pouch) – between the right lobe of the liver and the right kidney

The hepatorenal recess is the deepest part of the peritoneal cavity when lying supine. It is therefore the most likely place for fluid to accumulate in a patient lying flat. It is here that Focused Assessment with Sonography in Trauma (FAST) scanning is most likely to detect bleeding.

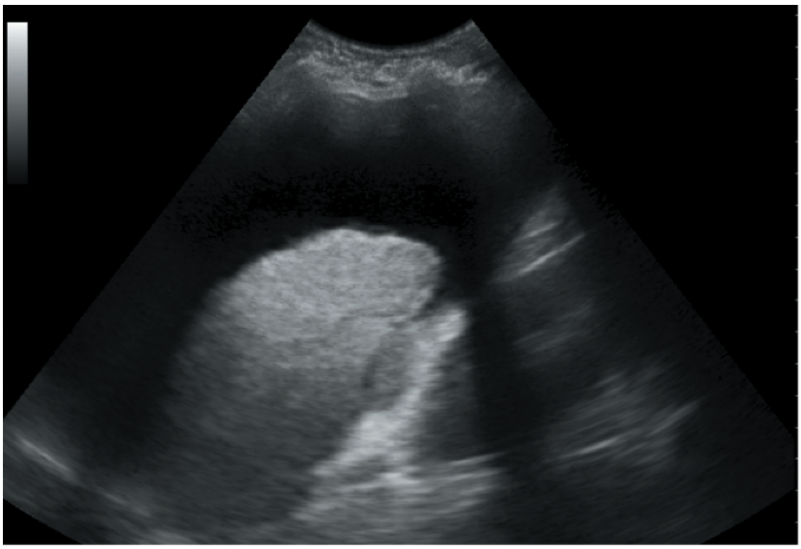

Fig 28. Ultrasound scan showing free fluid in the hepatorenal recess.

The Spleen

The adult spleen is the largest of the lymphatic organs and is located in the left upper quadrant. It varies in size but is typically 7-14 cm in length and weighs between 150 and 200 grams. **The spleen usually lies between the 9th and 11th ribs on the left side and the anterior notch reaches the mid-axillary line anteriorly.**

The diaphragmatic surface is convexly curved to fit the concavity of the diaphragm. The anterior and superior borders of the spleen are sharp and often notched, whereas the posterior and inferior borders are rounded.

The Gallbladder

The gallbladder is a small organ situated in the gallbladder fossa on the visceral surface of the liver. It is responsible for the storage of bile

that is produced by the liver. Bile is concentrated in the gallbladder and subsequently released into the small intestine.

It is a small pear-shaped organ that measures approximately 8 cm in length and 4 cm in diameter when fully distended. Its volume is approximately 30-50 mls. Its anterior surface adheres to the liver and its posterior surface is covered by visceral peritoneum.

The gallbladder has three parts:

- **The fundus**: this is the wide end that projects from the inferior surface of the liver. **It lies in the transpyloric plane of Addison and can be located at the tip of the 9th right costal cartilage in the mid-clavicular line.**
- **The body**: this is the large middle part of the gallbladder. It contacts the visceral surface of the liver, the transverse colon, and the superior (first) part of the duodenum.
- **The neck**: this is the narrow, tapered end of the gallbladder. It is continuous with the cystic duct, leading into the biliary tree.

At the junction of the neck of the gallbladder and the cystic duct lies an outpouching of the gallbladder wall that forms a mucosal fold called Hartmann's pouch. This is a common location for gallstones to become lodged and cause cholestasis.

The Pancreas

The pancreas is a glandular organ that has mixed endocrine and exocrine function:

- Endocrine function: controls blood glucose levels via the secretion of insulin and glucagon
- Exocrine function: secretes digestive enzymes into the duodenum

The pancreas is approximately 12-15 cm long and lies transversely and obliquely on the posterior abdominal wall behind the stomach. Here it crosses the L1-L2 lumbar vertebrae.

The pancreas can be divided into **five parts**:

1. **The head**:
   This is the widest part and lies within the 'C-shaped' curve created by the duodenum. The bile duct lies in a groove on its posterior surface.

2. **The uncinate process**:
   This is a prolongation of the head that extends superiorly and to the left to lie beneath the body.

3. **The neck**:
   This is located between the head and the body. **It lies in the transpyloric plane of Addison approximately 1-2 cm to the right of the midline.**

4. **The body**:
   This is the central part of the pancreas. It extends from the neck along a line running upwards and to the left for about 10 cm until it reaches the hilum of the spleen. It crosses the L2 vertebra during its course.

5. **The tail**:
   This is the end of the pancreas. It lies in close proximity to the hilum of the spleen. This is the only part of the pancreas that is intraperitoneal.

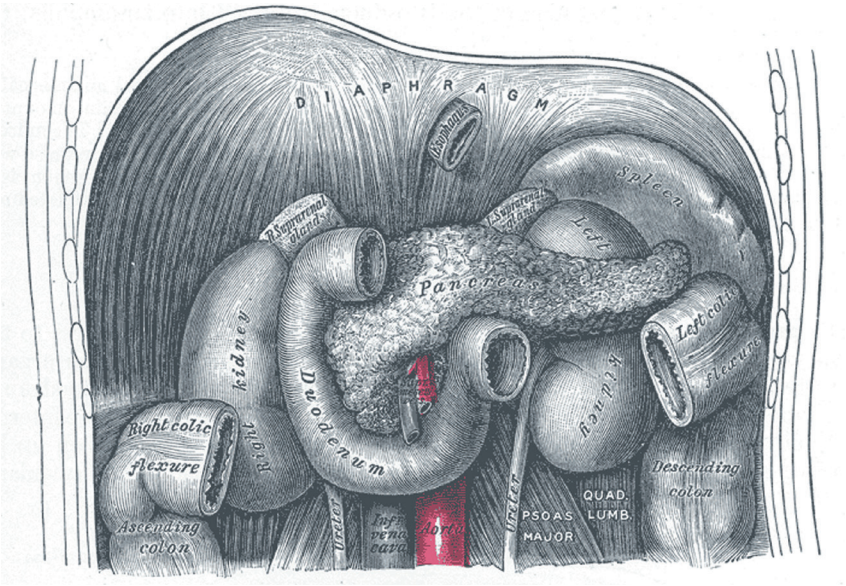

*Fig 29. The pancreas and its relations. **

The Kidneys

The kidneys are two retroperitoneal organs that lie on the posterior abdominal wall. They are responsible for electrolyte and fluid balance and also for the filtration and excretion of waste products from the blood.

Each kidney lies on its respective side of the vertebral column between the T12 and L3 vertebral levels. The right kidney lies slightly lower than the left because of the presence of the large right lobe of the liver. The kidney moves during respiration; one particular study noted that the maximal vertical motion of the superior pole of the kidney from its end-expiratory to its end-inspiratory position is around 40 mm.

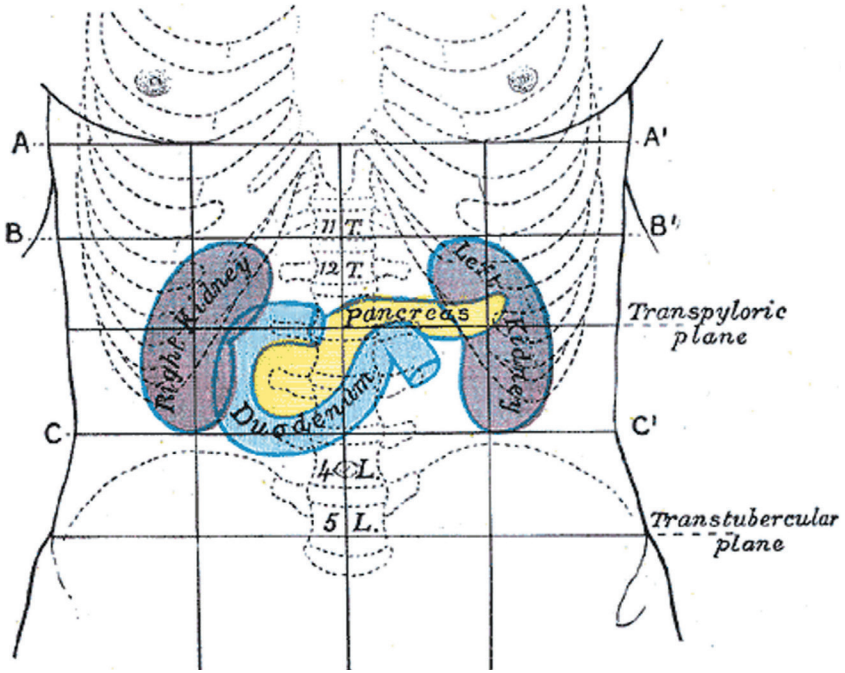

*Fig 30. The surface markings of the kidneys (in purple). **

At the concave medial margin of each kidney is a vertical cleft called the renal hilum. This is the point where the renal artery and vein enter and exit the kidney respectively. **The hila of the kidney lie approximately in the transpyloric plane of Addison at the L1 vertebral level**.

The Urinary Bladder

The urinary bladder is a hollow muscular organ situated at the base of the pelvis. **When the urinary bladder it is full it can be palpated above the symphysis pubis.**

The Abdominal Aorta

The abdominal aorta is the largest artery in the abdominal cavity. **It arises as a continuation of the thoracic aorta as it passes posterior to the median arcuate ligament of the diaphragm at the T12 vertebral level.** It descends caudally in the retroperitoneal space, anterior and to the left of the lumbar vertebral bodies and to the left of the inferior vena cava.

It is approximately 13 cm long and ends slightly to the left of the midline at the L4 vertebral level where it bifurcates into the right and left common iliac arteries.

The abdominal aorta has three main groups of branches:

1. **Single ventral gut arteries:**

    - Coeliac artery (T12) – supplies the stomach, abdominal oesophagus, liver, spleen, superior pancreas, and superior duodenum
    - Superior mesenteric artery (L1) – supplies the distal duodenum, jejunum, ileum, ascending colon and part of the transverse colon
    - Inferior mesenteric artery (L3) – supplies the large intestine from the splenic flexure to the upper part of the rectum

2. **Paired visceral arteries:**

    - Middle adrenal arteries (L1) – supply the adrenal glands
    - Renal arteries (L2) – supply the kidneys
    - Gonadal arteries (L2/L3) – supply the testicles/ovaries

3. **Paired wall arteries:**

    - Inferior phrenic arteries (T12) – supply the diaphragm
    - Four paired lumbar arteries (between L1 and L4) – supply the abdominal wall and spinal cord

It also gives off one single unpaired parietal artery, the median sacral artery, at the L4 vertebral level.

The aorta can be palpated using the fingers of both hands just above the umbilicus at the border of the aortic pulsation. Under normal circumstances the aorta should move upwards in a pulsatile fashion. An outwards movement of an enlarged aorta is suggestive of an abdominal aortic aneurysm (AAA).

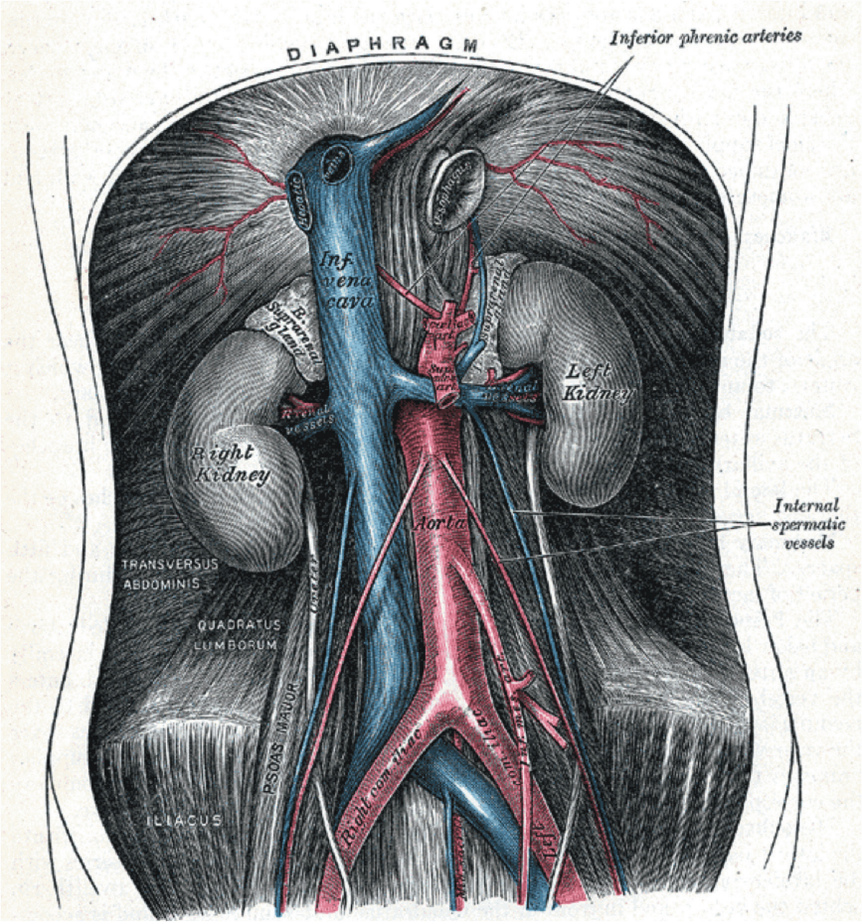

*Fig 31. The anatomical position and relations of the abdominal aorta and inferior vena cava.**

An abdominal aortic aneurysm is defined as an enlargement of the aorta at least 1.5 times its normal diameter or greater than 3 cm in total. The majority of cases occur in the lower abdomen infra-renally. Most AAA's are small and not immediately dangerous but they have a tendency to grow over time and become prone to rupture, particularly when reaching a size greater than 6 cm in diameter. The estimated rupture rate of aneurysms larger than 6 cm in diameter is approximately 10% and this rises to greater than 30% for aneurysms greater than 8 cm in diameter. AAAs can be readily visualized with bedside ultrasound examination and if detected early can be repaired surgically or via endovascular stenting.

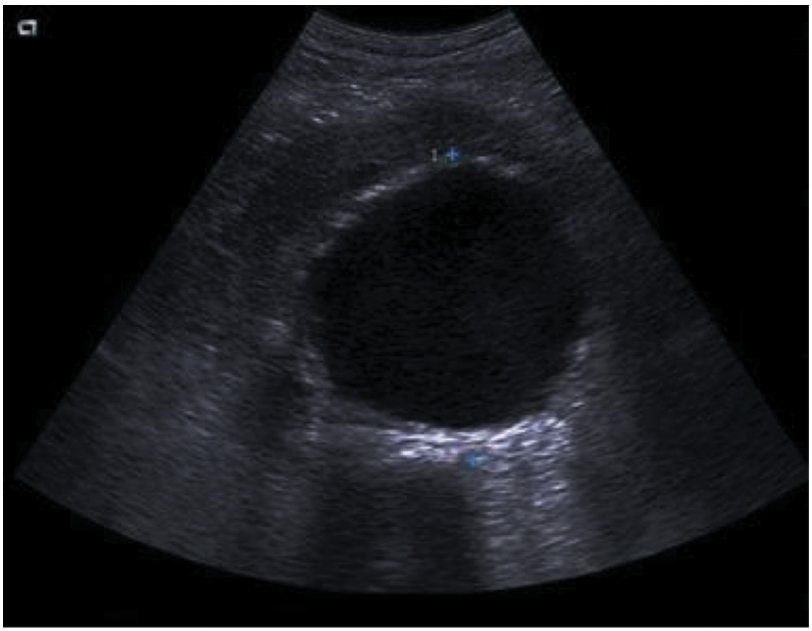

Fig 32. Bedside ultrasound showing a large AAA.

The Inferior Vena Cava

The inferior vena cava carries deoxygenated blood from all of the structures lying below the diaphragm into the right atrium of the

heart. **It arises as the union of the right and left common iliac veins at the L5 vertebral level.**

It ascends upwards in the retroperitoneal space, to the right of the lumbar vertebral bodies and to the right of the aorta. It pierces the central tendon of the diaphragm at the T8 vertebral level to enter the thorax. It then almost immediately enters the pericardium before draining into the right atrium.

The inferior vena cava receives tributaries from:

- Common iliac veins (origin at L5) – drain lower limbs and gluteal regions
- Lumbar veins (between L1 and L5) – drain the posterior abdominal wall
- Right gonadal vein (L2) – drains the right testis/ovary
- Renal veins (L1) – drain the kidneys, left adrenal gland, left testis/ovary
- Right adrenal vein (L1) – drains the right adrenal gland
- Right, middle and left hepatic veins (T8) – drain the liver
- Right and left inferior phrenic veins (T8) – drain the diaphragm

The Inguinal Canal

The inguinal canal is an oblique, inferomedially directed passage through the inferior part of the anterior abdominal wall. It lies parallel and just superior to the medial half of the inguinal ligament.

The inguinal canal acts as a pathway by which structures can pass from the abdominal wall to the external genitalia. The structures that pass through the canal differ between males and females.

In males the following pass through the inguinal canal:

- The spermatic cord and its coverings
- The ilioinguinal nerve

In females the following pass through the inguinal canal:

- The round ligament of the uterus
- The ilioinguinal nerve

The ilioinguinal nerve pierces the internal oblique muscle and passes through the superficial inguinal ring. It does not, however, pass through the deep inguinal ring, and therefore only passes through part of the inguinal canal.

The 'mid-inguinal point' is situated halfway between the anterior superior iliac spine and the pubic symphysis. This is the anatomical point at which the femoral artery crosses into the lower limb.

This should not be confused with the 'midpoint of the inguinal ligament'. The inguinal ligament runs from the anterior superior iliac spine to the pubic tubercle and the midpoint of the inguinal ligament is situated halfway between these structures.

The deep inguinal ring is an outpouching of the transversalis fascia that forms the entrance to the inguinal canal. It is situated just superior to the midpoint of the inguinal ligament and just lateral to the inferior epigastric artery. The deep inguinal ring transmits the spermatic cord in the male and the round ligament of the uterus in the female.

The superficial inguinal ring is a triangular aperture in the external oblique aponeurosis that forms the exit of the inguinal canal. It is formed by the evagination of the external oblique and is situated immediately above the crest of the pubis, 1 cm above and superolateral to the pubic tubercle.

The spermatic cord can be palpated as it passes medial to the pubic tubercle whilst descending into the scrotum.

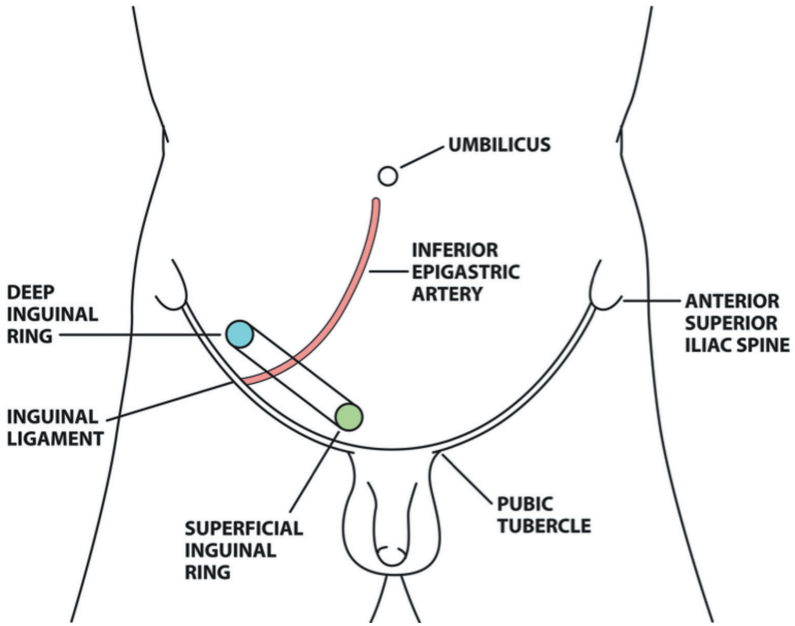

Fig 33. Surface anatomy of the inguinal canal

An inguinal hernia is a protrusion of the abdominal cavity contents through the inguinal canal. There are two main types:

- Indirect (75%) – these originate lateral to the inferior epigastric artery and follow the path of the spermatic cord or round ligament through the internal inguinal ring and along the inguinal canal
- Direct (25%) – these originate medial to the inferior epigastric artery and protrude through the posterior wall of the inguinal canal

Indirect inguinal hernias can be distinguished from direct inguinal hernias by the presence of the following features:

- They are elliptical in shape (compared with direct hernias that are round)
- They are less likely to be easily reducible
- They are less likely to reduce spontaneously on reclining

- They are slow to appear on standing (compared with direct hernias that appear immediately)
- They can be reduced superiorly then supero-laterally (compared with direct hernias that reduce superiorly then posteriorly)
- They can be controlled by pressure over the deep inguinal ring
- They are more prone to strangulation (because of narrow neck of deep inguinal ring)
- They can extend into the scrotum

A femoral hernia is a protrusion of the abdominal cavity contents through the femoral canal. They occur below and lateral to the pubic tubercle, as compared to inguinal herniae, which occur above and medial to the pubic tubercle. Femoral herniae are also more easily seen with the patient lying supine.

Langer's Lines and Surgical Incisions

Langer's lines, which are sometimes referred to as the skin cleavage lines, are a series of lines drawn topographically across the human body. They correspond to the natural orientation of collagen fibres in the dermis and usually lie parallel to underlying muscle fibres. They are an important consideration in surgery and if incisions are made in the direction of Langer's lines they tend to heal better and produce less scarring than those that cross them.

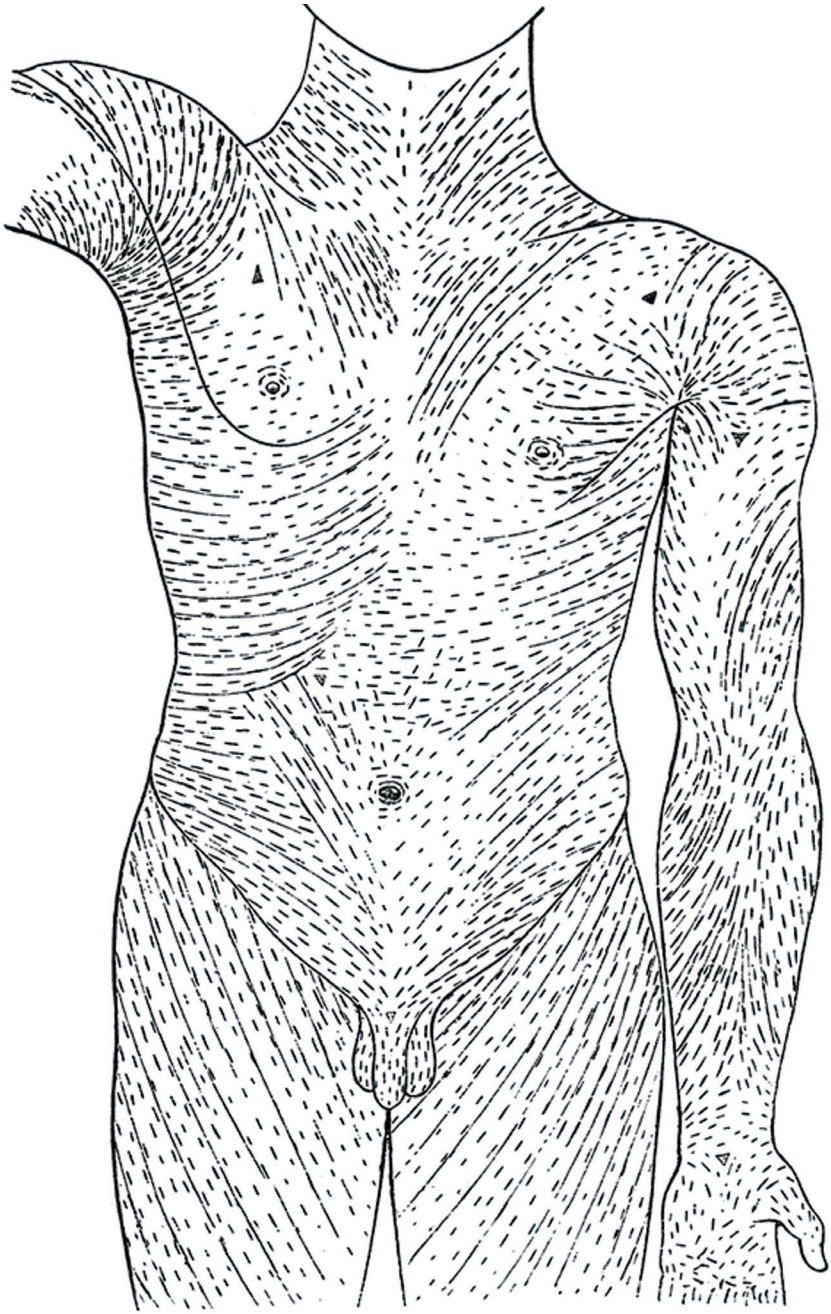

Fig 34. A topographical map of Langer's lines.[#]

There are numerous different types of surgical incisions that are used in a variety of different surgical scenarios. Ideally an incision should provide easy access to the desired structures, be aesthetically pleasing and heal quickly with minimal scarring. Additionally, muscles should be split, not cut, and the incision should be amenable to extension if required.

Some of the most commonly used abdominal incisions include:

1. **Subcostal incision:**
   A standard subcostal incision, sometimes referred to as the Kocher subcostal incision, starts at the midline, approximately 2-5 cm below the xiphoid and runs about 2.5 cm below and parallel to the costal margin. It allows access to the gallbladder, biliary tract and spleen.

2. **Paramedian incision:**
   The paramedian incision is made 2-5 cm to the left or right of the midline over the medial aspect of the transverse convexity of the rectus. It allows access to lateral lying structures such as the kidneys, adrenals and spleen.

3. **Midline incision:**
   This incision is made in the midline and can extend from the xiphoid process to below the umbilicus. The incision should be curved around the umbilicus if it is to extend this far. Virtually all abdominal procedures can be performed through a midline incision.

4. **McBurney incision:**
   The McBurney incision is made obliquely starting laterally above McBurney's point and ending medially below it. It is the incision used for most appendicectomies but can also be used in the left iliac fossa for left-sided colonic pathology.

5. **Pfannenstiel incision:**
   This is a 12 cm convex incision, located at the suprapubic skin crease approximately 5 cm superior to the pubic

symphysis. It allows access to the lower gastrointestinal tract, urinary tract and the pelvic reproductive organs.

6. **Transverse incision:**
   The transverse incision is made slightly lateral and inferior to the umbilicus. It allows access to the colon, duodenum, and pancreas, and is fairly commonly used due to the low risk of damage to the nerve supply to the abdominal muscles.

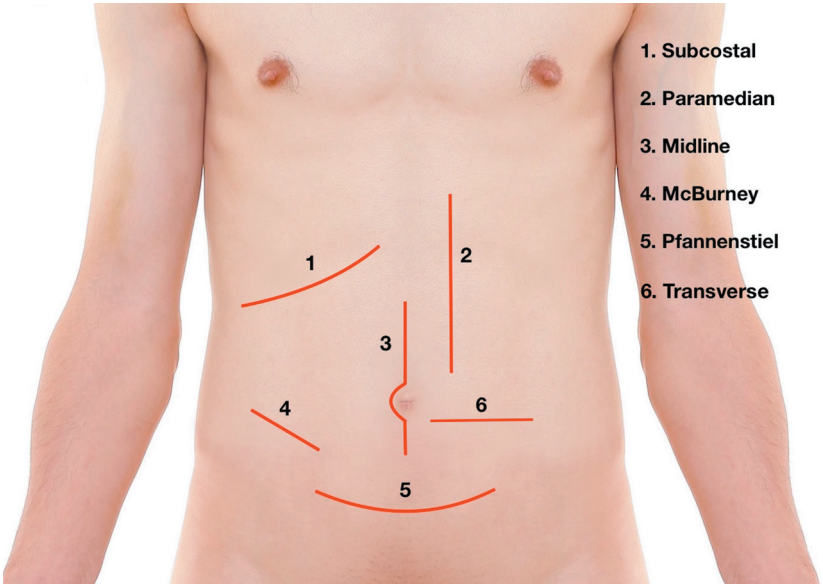

Fig 35. Commonly used abdominal incisions.

4

Upper Limb

The Scapula, Clavicle and Shoulder

The scapula connects the humerus with the clavicle. It forms the back of the shoulder girdle and is a flat bone that is roughly triangular in shape.

The acromion process can be palpated as a lateral extension of the spine of the scapula. It articulates with the clavicle at the acromioclavicular joint, which can be palpated as a small indentation at the end of the clavicle.

The spine, superior angle, inferior angle, and the medial border of the scapula can all be readily palpated posteriorly.

The deltopectoral triangle is a useful surface landmark formed by the superior border of pectoralis major, the anterior border of the deltoid muscle and the clavicle. The coracoid process can be palpated anteriorly beneath the clavicle inside the lateral aspect of the deltopectoral triangle

The clavicle lies horizontally between the sternum and the acromion process of the scapula. It is subcutaneous and easily palpable along its entire length.

The shoulder joint is a multiaxial synovial ball and socket joint formed by the articulation of the glenoid cavity of the scapula and the head of the humerus.

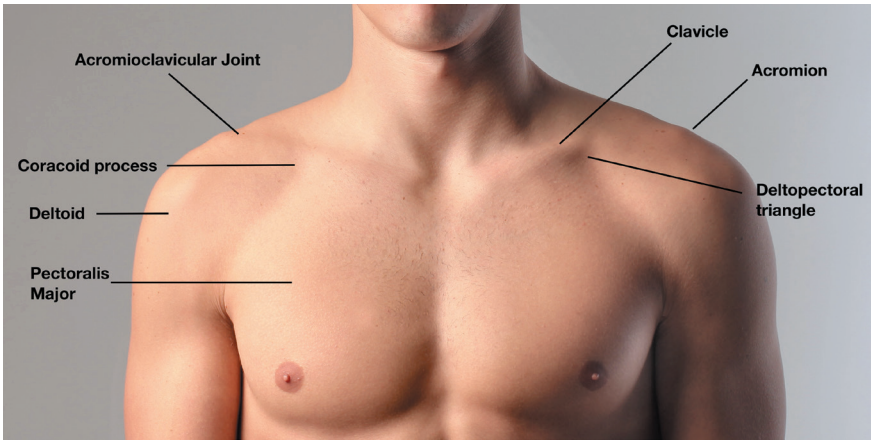

Fig 36. The surface markings of the scapula and clavicle.[§]

The Humerus and Elbow

The humerus is a long bone that extends from the scapula at the shoulder to the radius and ulna at the elbow.

The head of the humerus can be palpated in the axilla when the shoulder is held in an abducted position. The lesser tuberosity of the humerus can be palpated just lateral to the coracoid process. Movement of the lesser tuberosity can be felt as the arm is internally and externally rotated.

The elbow joint is a synovial hinge joint formed by the humerus and its articulation with the radius and ulna. When the elbow is held in an extended position the medial and lateral epicondyles can be palpated on either side of the olecranon of the ulna, which itself can be palpated posteriorly between these two points.

When the elbow is flexed these three points form a triangle. This triangle is useful in clinical practice when attempting to distinguish a supracondylar fracture from an elbow dislocation. The triangle is preserved in the presence of a supracondylar fracture but the

olecranon comes into line with the epicondyles in the presence of a dislocation.

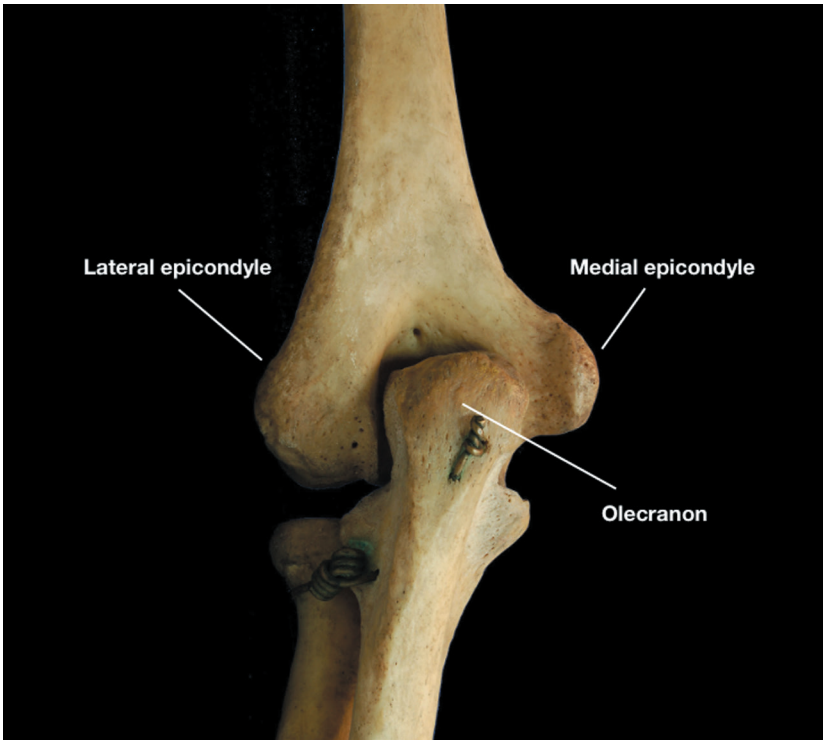

Fig 37. The posterior surface markings of the medial and lateral epicondyles and the olecranon.

The Radius, Ulna and Wrist

The radius is a long bone of the forearm that extends from the elbow to the wrist and articulates in four separate places:

- At the elbow joint between the radial head and the capitellum of the humerus
- At the proximal radio-ulnar joint between the radial head and the radial notch of the ulna

- At the wrist joint between the distal radius and the carpal bones
- At the distal radio-ulnar joint between the ulnar notch of the radius and head of the ulna

The radial head can be palpated in the hollow depression just posterior and distal to the lateral epicondyle of the extended elbow. Movement of the head can be felt here as the forearm is supinated and pronated.

The ulna is a long bone of the forearm. It also extends from the elbow to the wrist and lies parallel to the radius. It articulates in three places:

- At the elbow between the trochlear notch of the ulna and the trochlea of the humerus
- At the proximal radio-ulnar joint between the radial notch of the ulna and the radial head
- At the distal radio-ulnar joint between the head of the ulna and the ulnar notch of the radius

The entire posterior border of the ulna is subcutaneous and is easily palpable along its length.

The styloid processes of the ulnar and radius can be palpated on either side of the wrist joint and can easily be identified on plain X-rays. The dorsal tubercle of Lister can be palpated posteriorly on the posterior aspect of the distal radius.

Fig 38. The ulnar and radial styloid demonstrated on plain X-ray.[§]

The commonest type of wrist fracture is a fracture of the distal radius with dorsal displacement of the distal fragment. This is sometimes referred to as a Colles' fracture, named after the Irish surgeon Abraham Colles, who first described it. This fracture results in the very characteristic "dinner-fork" deformity with the area distal to the fracture being raised above the area proximal. This makes this fracture one of the easiest to identify without radiography.

Fig 39. The classic "dinner-fork" deformity associated with Colles' fracture.

The Brachial Artery and Profunda Brachii

The brachial artery is the continuation of the axillary artery beginning at the lower margin of teres major. It initially lies medial to the humerus and then spirals around it to lie anterior to it. It is superficial throughout its course and is accompanied by venae commitantes. It is the main source of blood to the arm.

Immediately distal to teres major it gives rise to the profunda brachii (the deep artery of the arm). The profunda brachii passes posteriorly between the long and medial head of triceps with the radial nerve into the spiral groove of the humerus before breaking up into its terminal branches.

The pulse of the brachial artery is palpable on the anterior aspect of the elbow, medial to the biceps tendon. It is at this site that blood pressure is often measured using a stethoscope and sphygmomanometer.

The brachial artery ends in the cubital fossa at the level of the neck of the radius by bifurcating into its terminal branches, the radial and ulnar arteries.

The brachial artery can be easily injured by supracondylar fractures of the elbow. The sharp anterior margin of the upper fragment can kink or damage the vessel. The brachial artery can also be damaged during reduction. For this reason the radial pulse must always be palpated during the assessment of this injury.

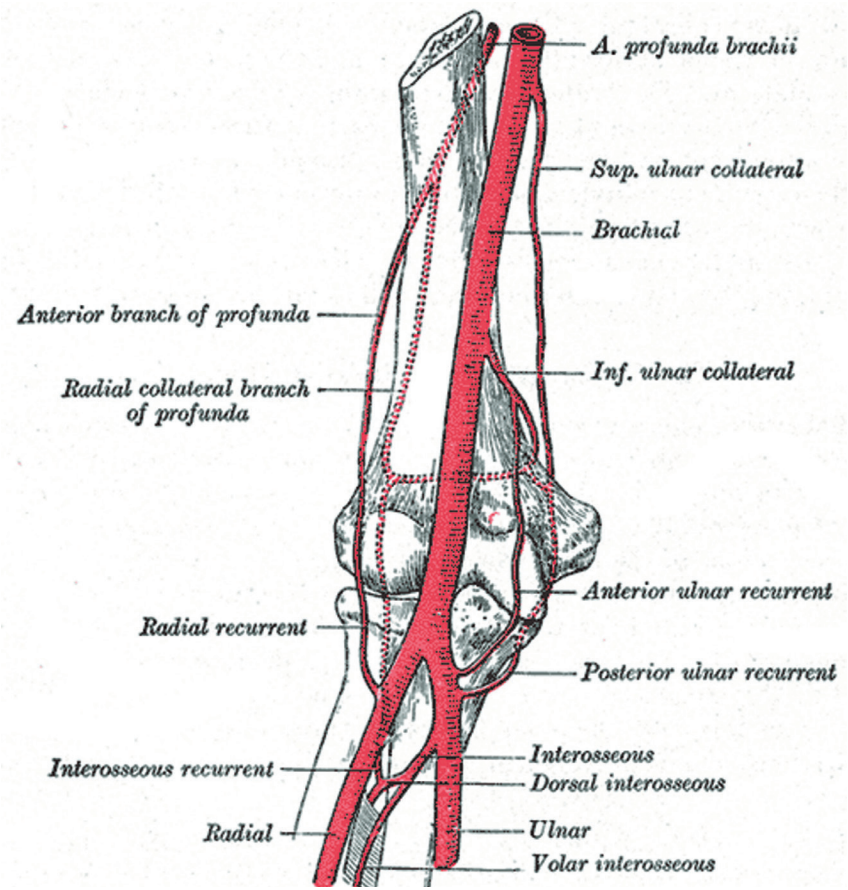

*Fig 40. The anatomical position and course of the brachial artery and profounda brachii.**

The Radial and Ulnar Arteries

The radial artery arises at the terminal bifurcation of the brachial artery in the cubital fossa at the level of the neck of the radius. The radial artery supplies the posterior aspect of the forearm and serves as a landmark for the division between the anterior and posterior compartments of the forearm, with the posterior compartment lying just lateral to the artery.

Distally in its course it passes onto the lower end of the radius where its pulse is palpable as it lies lateral to the tendon of flexor carpi radialis. It then winds laterally around the wrist, passing through the anatomical snuffbox.

The ulnar artery arises at the terminal bifurcation of the brachial artery in the cubital fossa at the level of the neck of the radius. The ulnar artery supplies the anterior aspect of the forearm.

At the wrist it lies lateral to flexor carpi ulnaris before passing superficial to the flexor retinaculum to enter the hand. It is easily palpable at this point.

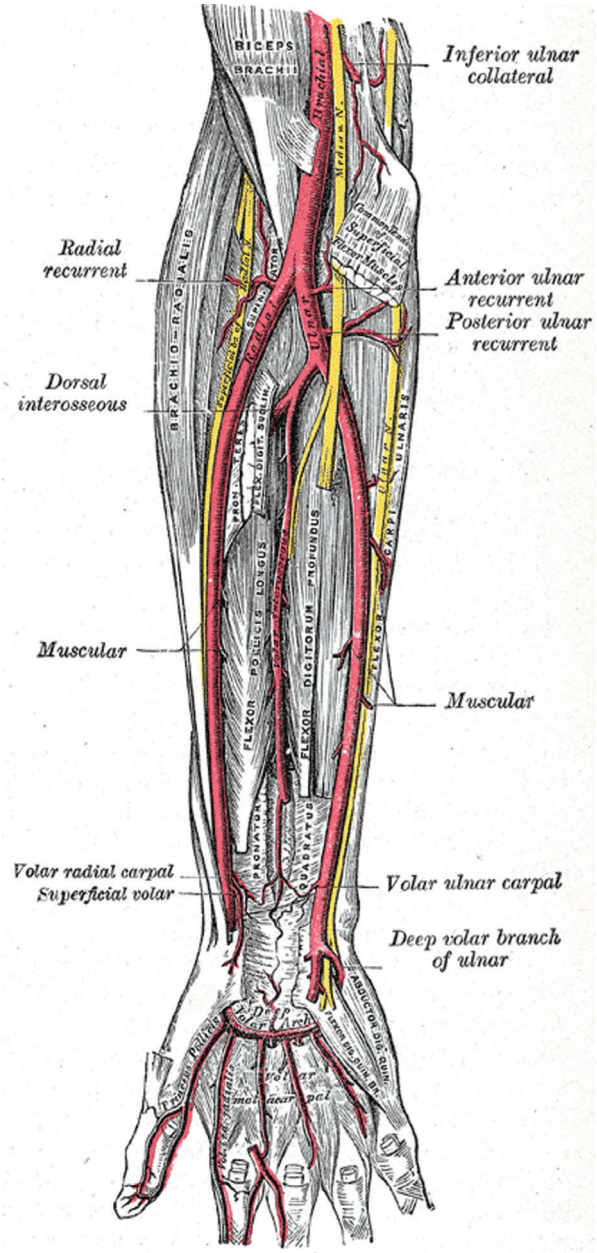

*Fig 41. The anatomical position and course of the radial and ulnar arteries.**

The Brachial Plexus

The brachial plexus is a network of nerves that supplies innervation to the skin and musculature of the upper limb. It is subdivided into roots, trunks, divisions and branches and the order in which these division occur can be remembered using the mnemonic '**R**ugby **T**eams **D**rink **C**old **B**eers':

- **R**oots
- **T**runks
- **D**ivisions
- **C**ords
- **B**ranches

There are typically 5 roots, 3 trunks, 6 divisions, 3 cords and 5 terminal branches. The roots pass anterior to scalenus medius and posterior to scalenus anterior before entering the base of the neck.

The roots converge in the base of the neck to form the three trunks. **The trunks pass laterally across the posterior triangle of the neck, where they are palpable and pass over the 1st rib posterior to the 3rd part of the subclavian artery before descending behind the clavicle.**

Behind the middle third of the clavicle each trunk divides into two branches to form the six divisions. One division passes anteriorly and one posteriorly and are therefore known as the anterior and posterior divisions.

The divisions then leave the posterior triangle of the neck and pass into the axilla where they regroup to become the three cords. The three cords give rise to five major branches in the axilla and the proximal part of the upper limb:

- Axillary nerve (C5 and C6)
- Musculocutaneous nerve (C5-C7)
- Radial nerve (C5-C8 and T1)
- Median nerve (C6-C8 and T1)
- Ulnar nerve (C8 and T1)

In addition to the five major branches there are several smaller branches that arise from various parts of the brachial plexus.

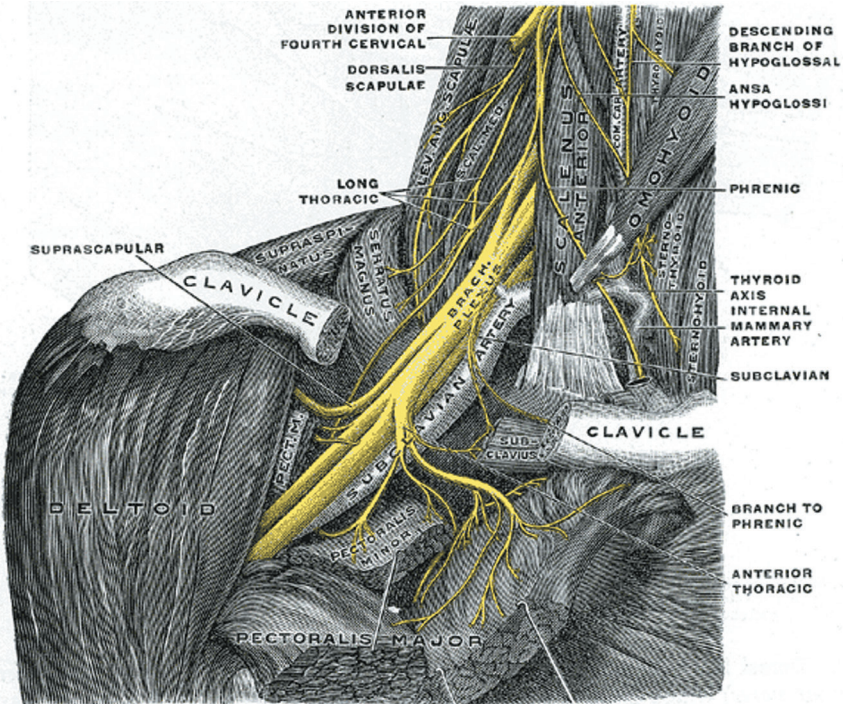

*Fig 42. The anatomical position and relations of the brachial plexus.**

The Axillary Nerve

The axillary nerve is formed within the axilla as a direct continuation of the posterior cord of the brachial plexus.

The axillary nerve is not palpable but it is important to know its course when making surgical incisions in the upper arm and shoulder. Of particular importance is the position of the anterior branch of the axillary nerve as it winds around the surgical neck of the humerus, beneath the deltoid muscle.

The axillary nerve is of great clinical importance when assessing patients with anterior shoulder dislocation. It is the most commonly injured nerve structure associated with this dislocation and is injured in 35-40% of cases. For this reason sensation over the lateral aspect of the shoulder (the deltoid badge area), which is supplied by the axillary nerve, should be tested in all shoulder dislocations.

The Radial Nerve

The radial nerve is a major branch of the brachial plexus that arises as a continuation of the posterior cord. **Of particular importance is its passage through the spiral groove of the humerus between the lateral and medial heads of triceps.**

The radial nerve is impalpable but it is prone to damage at four particular points throughout its course:

- In the axilla
- In the spiral groove
- At the elbow
- In the forearm

The radial nerve can be damaged in the axilla by glenohumeral joint dislocation or fracture of the head of the humerus. It can also occur due to excessive pressure in the axilla, for example 'Saturday night syndrome' where the arm has been hung over the back of a chair in a drunken stupor.

The commonest cause of a radial nerve palsy is external compression or trauma to the radial nerve as it traverses the spiral groove in the mid-humerus. Injuries here are commonly associated with fractures of the humerus.

The deep branch of the radial nerve can be damaged in isolation at the elbow by fracture of the radial head or by posterior dislocation of the elbow.

Stabbing or laceration of the forearm, particularly in the region of brachioradialis, can result in isolated damage to the superficial branch of the radial nerve.

The posterior interosseous branch of the radial nerve may also be damaged in the forearm, either by an injury to the radial head or by becoming entrapped in the supinator muscle under the arcade of Frohse.

The radial nerve can be blocked with local anaesthetic at the wrist and this is often utilized when repairing damaged structures in the hand or during hand surgery. The superficial branch of the radial nerve is the primary sensory branch in the hand. This branch passes posteriorly, emerging from under the tendon of brachioradialis proximal to the radial styloid, and passes over the tendons of the anatomical snuffbox. It then terminates as cutaneous branches to the dorsum of the hand.

The block is best performed with the wrist held in slight dorsiflexion and local anaesthetic should be infiltrated subcutaneously around the radial side and dorsum of the wrist approximately 3 cm proximal to the radial styloid. The needle should be aimed medially towards the radial artery but with care taken not to penetrate the vessel itself.

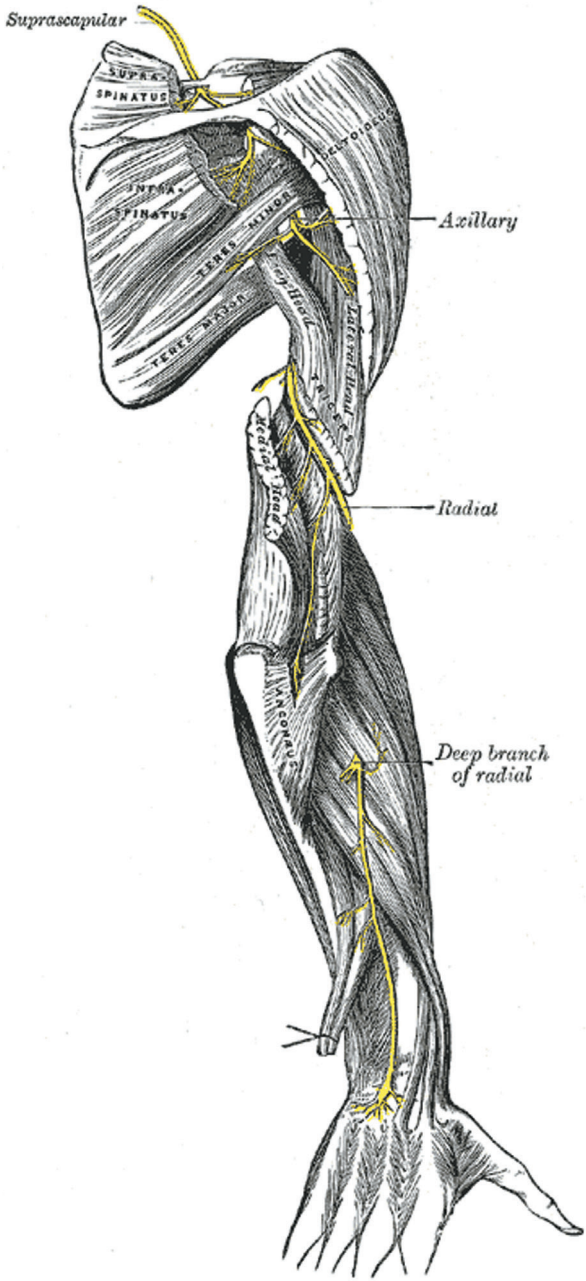

*Fig 43. The anatomical course of the radial nerve.**

The Median Nerve

The median nerve is a major branch of the brachial plexus that is derived from the medial and lateral cords. It initially lies anterior to the axillary artery, and then lateral to it, and then descends down the arm lateral to the brachial artery. It then crosses over the brachial artery at the level of the mid-humerus to lie medial to the artery in the cubital fossa.

The median nerve passes beneath the bicipital aponeurosis at the elbow and leaves the cubital fossa between the two heads of pronator teres to enter the anterior compartment of the forearm. It gives off its anterior interosseous branch just below this point.

In the forearm the median nerve travels between flexor digitorum superficialis and flexor digitorum profundus, before emerging between flexor digitorum superficialis and flexor pollicis longus about 5 cm proximal to the wrist. Here it gives off its palmar cutaneous branch and then passes deep to the flexor retinaculum between the tendons of flexor digitorum superficialis and flexor carpi radialis.

The median nerve can be located at the wrist between the tendons of palmaris longus and flexor carpi radialis. It should be noted that palmaris longus is absent in around 15% of the population and if this is the case the median nerve can be located 5-10 mm medial to flexor carpi radialis.

The median nerve is impalpable but is prone to damage at the elbow and at the wrist. The commonest mechanism of injury at the elbow is a supracondylar fracture of the humerus. The median nerve can be damaged by injury at the wrist by lacerations proximal to the flexor retinaculum. The nerve can also be compressed in the carpal tunnel.

Injury to the median nerve at the elbow causes the characteristic papal benediction sign. This sign does not occur with wrist injuries, however, due to the anterior interosseous nerve being intact.

Fig 44. Papal benediction of the hand.

The median nerve can be blocked with local anaesthetic at the wrist and this is often utilized when repairing damaged structures in the hand or during hand surgery. **The block can be performed by infiltrating local anaesthetic between the tendons of palmaris longus and flexor carpi radialis approximately 2.5 cm proximal to the flexor retinaculum, which can be located underneath the wrist crease.**

The Ulnar Nerve

The ulnar nerve is a major branch of the brachial plexus that arises as a continuation of the medial cord.

It then lies between the intermuscular septum and the medial head of triceps, passing posterior to the medial epicondyle before entering the forearm between the two heads of flexor carpi ulnaris. **It is easily palpable at the medial epicondyle and is vulnerable to injury at this point.**

The ulnar nerve lies lateral to the tendon of flexor carpi ulnaris at the wrist. It can be located between the ulnar artery and the tendon of flexor carpi ulnaris. It then passes superficial to the flexor retinaculum and enters the hand through the ulnar canal (Guyon's canal).

The ulnar nerve can be blocked with local anaesthetic at the wrist and this is often utilized when repairing damaged structures in the hand or during hand surgery. **The block can be performed by infiltrating local anaesthetic under the tendon of flexor carpi ulnaris close to its distal attachment just above the styloid process of the ulna.** Alternatively the needle can be inserted medial to the ulnar artery, lateral to the tendon of flexor carpi ulnaris at the level of the wrist crease, directed towards the styloid process of the ulna.

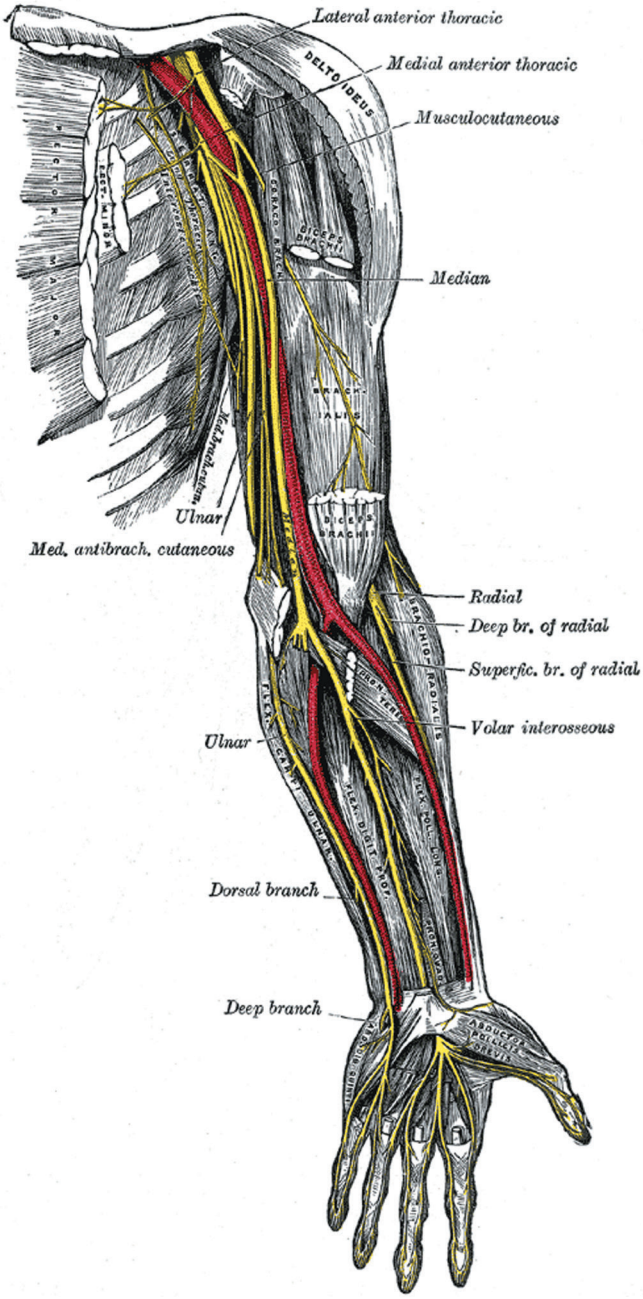

*Fig 45. The course of the median and ulnar nerves.**

The Cubital Fossa

The cubital fossa is a transitional area that is situated between the upper arm and forearm. It is easily located as a depression that is present on the anterior surface of the elbow.

It is triangular in shape and has the following borders:

- Superior border – a line transecting the epicondyles of the humerus
- Lateral border – medial border of brachioradialis
- Medial border – lateral border of pronator teres

The contents of the cubital fossa, from medial to lateral, are:

- Median nerve (most medial)
- Brachial artery
- Biceps tendon
- Radial nerve (most lateral)

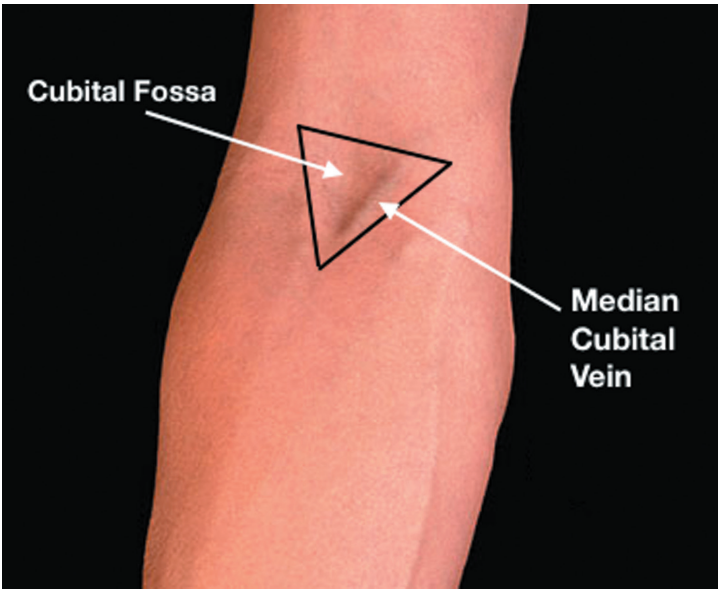

Fig 46. The position of the median cubital vein within the cubital fossa.

The median cubital vein is located superficially within the roof of the cubital fossa. This vein connects the basilic and cephalic veins and because of its relative ease of access is a common site for venepuncture and peripheral venous cannulation.

The Carpal tunnel

The carpal tunnel is a passageway on the palmar side of the wrist that connects the forearm to the middle compartment of the deep plane of the hand.

It is formed by two layers, the carpal arch and the flexor retinaculum:

1. **The carpal arch forms the floor of the carpal tunnel**: It is concave on the palmar side and is formed laterally by the scaphoid and trapezium tubercles and medially by the hook of the hamate and the pisiform bones.
2. **The flexor retinaculum forms the roof of the carpal tunnel**. It is a strong, fibrous band that covers the carpal bones on the palmar side of the hand near the wrist. It is attached medially to the pisiform bone and the hook of the hamate bone. Laterally it attaches to the tubercle of the scaphoid bone, and to the medial part of the trapezium bone.

The carpal tunnel contains a total of nine flexor tendons (but not the muscles themselves), surrounded by a synovial sheath, and the median nerve. The tendons contained within the carpal tunnel are:

- Flexor digitorum profundus (four tendons)
- Flexor digitorum superficialis (four tendons)
- Flexor pollicis longus (one tendon)

Carpal tunnel syndrome is an entrapment neuropathy of the median nerve. It causes weakness and parasthesia in the distribution of the median nerve.

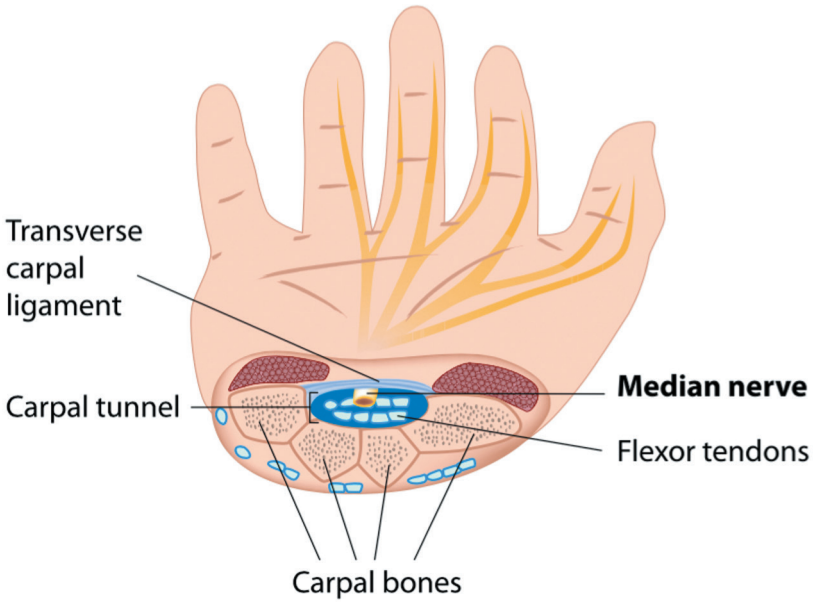

Fig 47. The carpal tunnel and the position of the median nerve within it.[§]

The Anatomical Snuffbox

The anatomical snuffbox is a triangular depression located on the lateral aspect of the dorsum of the hand. It is most prominent when the thumb is abducted.

It has three borders, a floor, and a roof:

- Medial (ulnar) border: tendon of extensor pollicis longus
- Lateral (radial) border: tendons of extensor pollicis brevis and abductor pollicis longus
- Proximal border: styloid process of the radius
- Floor: carpal bones (scaphoid and trapezium)
- Roof: skin

The main contents of the anatomical snuffbox are:

- The radial artery
- The superficial branch of the radial nerve
- The cephalic vein

The radial artery crosses the floor of the anatomical snuffbox obliquely, running deep to the extensor tendons. The radial pulse can be located here in some individuals.

The superficial branch of the radial nerve passes subcutaneously across the roof of the anatomical snuffbox, providing innervation to the skin of the lateral three and a half digits on the dorsum of the hand, and the associated palm area.

The cephalic vein arises within anatomical snuffbox from the dorsal venous network of the hand and then crosses it subcutaneously.

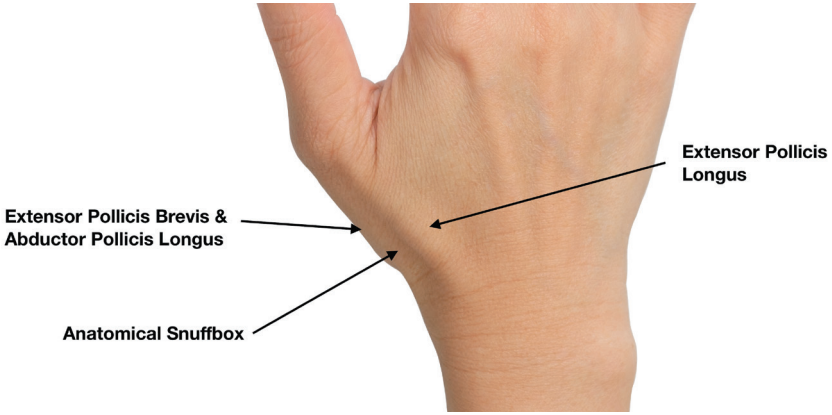

Fig 48. The anatomical snuffbox.

Within the anatomical snuffbox the scaphoid bone and the radius articulate to form part of the wrist joint. The scaphoid bone can be easily palpated within the anatomical snuffbox and tenderness in the anatomical snuffbox following a fall onto an outstretched hand should lead to suspicion of a scaphoid fracture.

5

Lower Limb

The Bony Pelvis and Hip

The bony pelvis is a ring-like skeletal structure that connects the spine to the lower limbs. It consists of the two hip bones, the sacrum, and the coccyx. The hip bones themselves are made up of three parts, the ilium, pubis and ischium. The hip joint should not be confused with the hip bone, and is the ball and socket synovial joint that articulates between the head of the femur and the acetabulum of the pelvis.

There are two very prominent palpable landmarks on the bony pelvis that serve as useful surface markings: the anterior superior iliac spine and the ischial tuberosity.

The anterior superior iliac spine (ASIS) is the anterior extremity of the iliac crest of the pelvis and is helpful in identifying other surface markings such as the midinguinal point and McBurney's point.

"True leg length" is measured from the ASIS to the medial malleolus of the ankle. This should not be confused with "apparent leg length", which is measured from the umbilicus to the medial malleolus.

The ischial tuberosity is a prominent point situated posteriorly on the superior ramus of the ischium. It is covered by the large gluteus maximus muscle when the hip is extended but can be palpated in the lower part of the buttock when the hip is flexed.

The Femur and Knee

The femur is a long bone that extends from the acetabulum at the hip to its articulation with the tibia and patella at the knee.

The greater trochanter of the femur is palpable on the lateral aspect of the thigh approximately one hands-breadth below the iliac crest.

The medial and lateral femoral condyles are two rounded areas that lie at the distal end of the femur. The medial femoral condyle is larger than the lateral femoral condyle as more weight bearing occurs on the inner aspect of the knee. The lateral femoral condyle is, however, more prominent and broader.

The outermost protrusion on the medial surface of the medial femoral condyle is referred to as the medial epicondyle and can be palpated by running the fingers medially from the patella with the knee flexed. Similarly there is an outer palpable protrusion on the lateral condyle that is referred to as the lateral epicondyle.

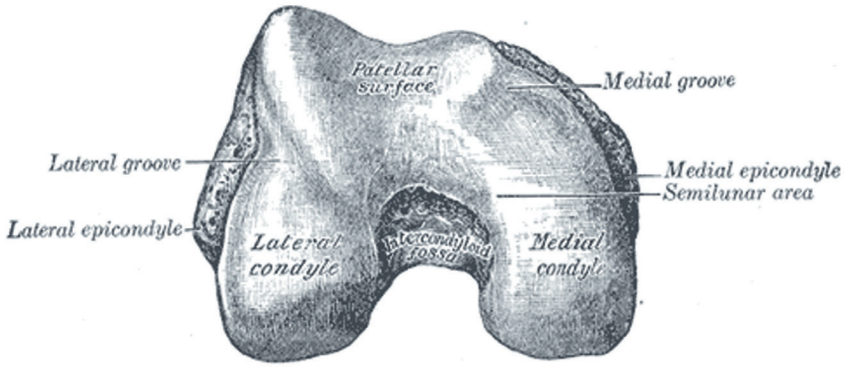

*Fig 49. The condyles and epicondyles at the lower end of the femur.**

The adductor tubercle is another bony prominence that can be palpated on the medial aspect of the femur just superior to the medial femoral condyle.

The knee joint consists of two articulations: one between the femur and tibia (the tibiofemoral joint), and one between the femur and the patella (the patellofemoral joint). The patella and the femur ligament are both easily palpable with the knee extended and relaxed on the anterior aspect of the knee joint. The patella ligament can be traced to its attachment at the tibial tuberosity inferiorly.

The Tibia, Fibula and Ankle

The tibia is the larger and stronger of the two bones found below the knee in the leg. It is situated on the medial side of the leg and extends from the knee to the ankle. The subcutaneous border of the tibia is palpable anteriorly on the leg throughout its length.

The tibia is widened at the proximal end by the medial and lateral tibial condyles. These are prominent landmarks on the leg that can be easily palpated just below the knee joint. The medial tibial condyle is larger than the lateral tibial condyle. When the knee is flexed the outer edges of the menisci can be palpated within the joint line. The medial and lateral collateral ligaments can also be palpated on either side of the knee and can be traced to their bony attachments.

The tibial tuberosity is a large elevation that is palpable on the anterior surface of the proximal tibia, slightly inferior to the point where the anterior surface of the medial and lateral tibial condyles ends. This point is important clinically in adolescents with Osgood-Schlatter's disease, which is inflammation of the patella ligament at the tibial tuberosity. It is characterised by a painful bony prominence at this point.

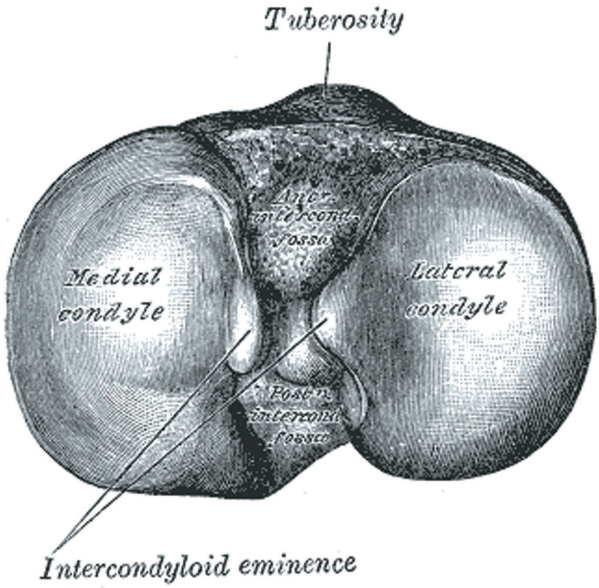

*Fig 50. The upper surface of the right tibia showing the condyles and the tibial tuberosity.**

The fibula is the smaller of the two bones present in the leg below the knee. It is found laterally to the tibia and is connected to it medially via the interosseous membrane, forming a syndesmosis joint.

The head of the fibula is palpable on the lateral aspect of the leg and the common peroneal nerve is located on the posterolateral surface of the neck of the fibula. The shaft of the fibula is mostly covered and impalpable but can be felt along the terminal 10 cm of its length superior to the ankle.

The ankle joint is a synovial hinge joint that is formed by the tibia, fibula and the talus. The medial and lateral malleoli are palpable on either side of the ankle. The lateral malleolus is formed by the lower end of the fibula and the medial malleolus is formed by the lower end of the tibia. The lateral malleolus descends further and is more elongated in shape than the medial malleolus.

The tendons of peroneus brevis and peroneus longus pass behind the lateral malleolus. The tendons of tibialis posterior, flexor digitorum longus, and flexor hallucis longus pass behind the medial malleolus. The posterior tibial artery and the tibial nerve also pass behind the medial malleolus.

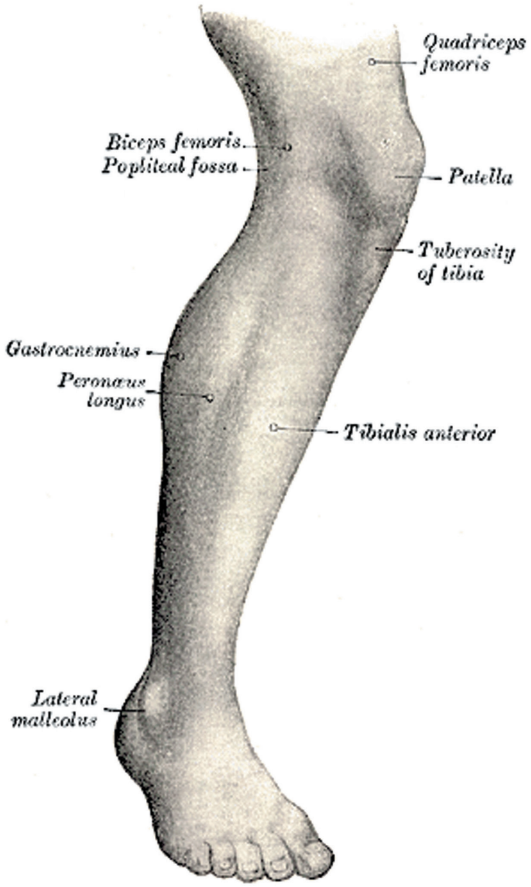

*Fig 51. Surface markings on the lateral aspect of the right leg.**

The base of 5th metatarsal in the foot is an important anatomical landmark when assessing patients with ankle injuries. The tendon of peroneus brevis extends from the lower part of the fibula to the base of the 5th metatarsal and is easily injured in ankle inversion injuries.

A Jones fracture is a fracture of the meta-diaphyseal junction of the 5th metatarsal caused by a significant adduction force to the forefoot with the ankle in plantar flexion. Tenderness at this point in a patient with an ankle injury should raise suspicion that this diagnosis may be present.

The Femoral Artery and the Femoral Triangle

The femoral artery is the main arterial supply to the lower limb. It is a continuation of the external iliac artery.

The femoral artery commences posterior to the inguinal ligament at the mid-inguinal point (halfway between the anterior superior iliac spine and the symphysis pubis).

It emerges from under the inguinal ligament with the femoral vein medial to it, and both lie within the femoral sheath. The femoral nerve lies lateral to it and outside the femoral sheath. It ends as it passes through the adductor hiatus (Hunter's canal) in adductor magnus to become the popliteal artery.

The main branch of the femoral artery is the profunda femoris. This is given off posterolaterally just below the femoral sheath, 3.5 cm below the inguinal ligament.

The femoral triangle is an anatomical region situated in the upper thigh area. It appears as a triangular depression that is situated inferiorly to the inguinal ligament when the thigh is flexed, abducted and laterally rotated.

The borders of the femoral triangle can be remembered by the mnemonic **'SAIL'** (The femoral triangle is shaped like the sail of a ship):

- Laterally – Medial border of **S**artorius
- Medially – Medial border of **A**dductor longus
- Superiorly – **I**nguinal **L**igament

Its floor is formed by pectineus and adductor longus medially and iliopsoas laterally. Its roof is formed by the fascia lata.

The following structures are contained within the femoral triangle from lateral to medial:

- Femoral nerve
- Femoral artery
- Femoral vein
- Femoral canal (contains deep inguinal lymph nodes and lymphatic vessels)

The femoral artery, vein and canal are contained with a fascial compartment known as the femoral sheath.

The femoral triangle is clinically important as it provides easy access to the femoral artery, which can be utilised for angioplasty, and to the femoral vein, which can be utilised for central venous cannulation. It also provides easy access to the femoral nerve, which can be utilised for femoral nerve blocks.

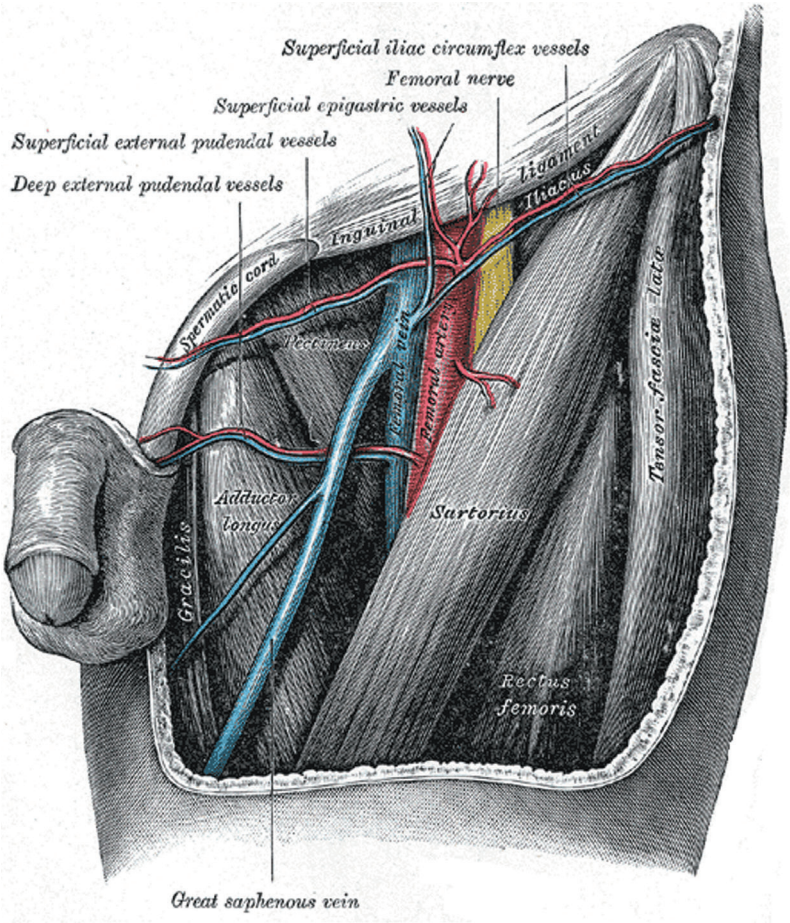

*Fig 52. The femoral triangle.**

The Popliteal Artery and the Popliteal Fossa

The popliteal artery begins as a continuation of the femoral artery as it traverses Hunter's canal (the adductor hiatus).

The popliteal pulse can be difficult to locate as it lies deep to the popliteal nerve and tibial nerve. It is best felt by flexing the knee with the patient prone and pushing the fingertips deep into the popliteal fossa.

The popliteal fossa is a diamond shaped depression situated at the back of the knee joint. It acts as the main conduit for the neurovascular structures entering and leaving the leg.

The borders of the popliteal fossa are:

- Superomedial border: semimembranosus
- Superolateral border: biceps femoris
- Inferomedial border: medial head of gastrocnemius
- Inferolateral border: lateral head of gastrocnemius and plantaris

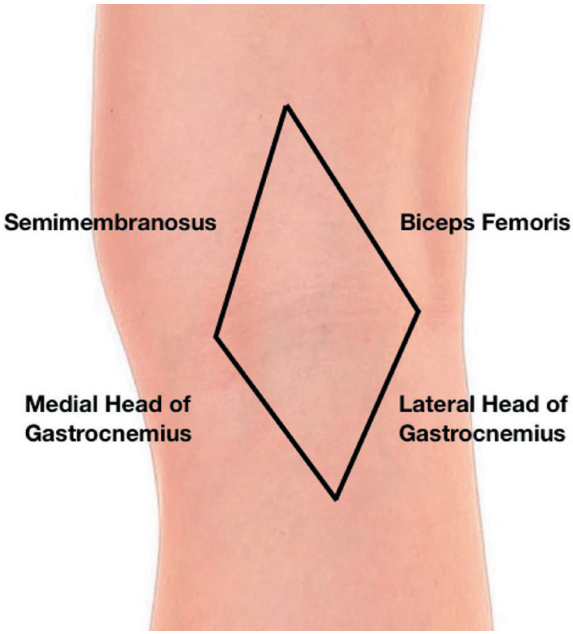

Fig 53. The right popliteal fossa.

The roof of the popliteal fossa is formed by (from superficial to deep):

- Skin
- Superficial fascia
- Deep (popliteal) fascia

The floor of the popliteal fossa is formed by:

- Popliteal surface of the femur
- Capsule of the knee joint
- Fascia covering the popliteus muscle

The contents of the popliteal fossa (from medial to lateral) are:

- Popliteal artery
- Popliteal vein
- Tibial nerve
- Common peroneal nerve

Popliteal artery aneurysms are the most common peripheral artery aneurysms and the second commonest type of aneurysm after abdominal aortic aneurysms. In 50-70% of cases they are bilateral. Because the fascia that forms the roof of the popliteal fossa is thick, strong, and non-compressible, they can compress other structures within the popliteal fossa, including the tibial nerve. This can result in weak or absent plantar flexion of the foot and paraesthesia of the foot and posterolateral leg. Popliteal artery aneurysms are easily palpable as a pulsatile mass within the popliteal fossa and an arterial bruit can sometimes be heard when auscultating over this area in their presence.

Foot Pulses

The dorsalis pedis artery arises at the anterior aspect of the ankle joint as a continuation of the anterior tibial artery. It supplies the tarsal bones and the dorsal aspect of the metatarsals and communicates with the plantar arterial supply to the foot via the deep plantar artery.

The dorsalis pedis pulse can be palpated on the dorsum of the foot, just lateral to the tendon of extensor hallucis longus.

The posterior tibial artery carries blood to the posterior compartment of the leg and the plantar surface of the foot from the popliteal artery via the tibial-peroneal trunk.

The posterior tibial pulse can be palpated halfway between the posterior border of the medial malleolus and the Achilles tendon.

These two foot pulses are often palpated when assessing for the presence of peripheral vascular disease.

The Great Saphenous Vein

The great saphenous vein is a large, subcutaneous, superficial vein of the leg. It is the longest vein in the body, running the entire length of the lower limb.

It is formed by the dorsal venous arch in the foot in combination with the dorsal vein of the great toe. **It then ascends up the medial side of the leg, passing anteriorly to the medial malleolus at the ankle.**

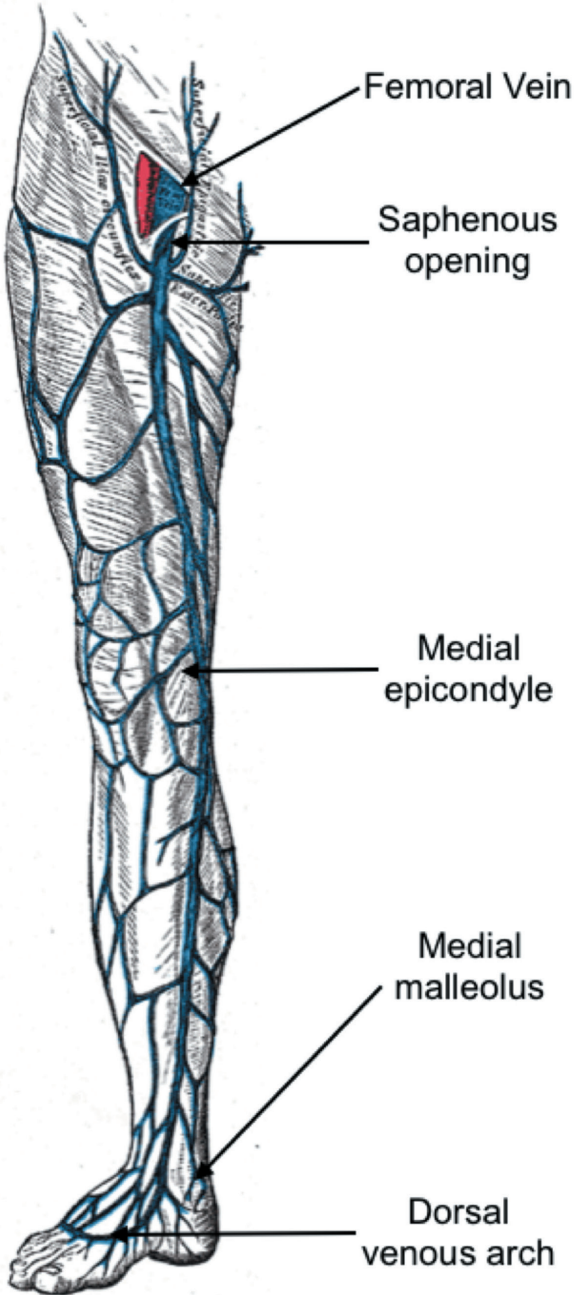

*Fig 54. The surface markings of the great saphenous vein.**

At the knee it runs over the posterior border of the medial epicondyle of the femur. It then courses anteriorly to lie on the anterior surface of the thigh before entering the saphenous opening in the fascia lata.

The great saphenous vein terminates by draining into the femoral vein immediately inferior to the inguinal ligament.

The great saphenous vein is used for vascular access via venous cut-down in the emergency trauma setting. The procedure can be performed by 'cutting down' anterior and above the medial malleolus.

The Sciatic Nerve

The sciatic nerve is a major nerve of the lower limb that is derived from the L4-S3 roots of the lumbosacral plexus. It supplies the muscles of the posterior thigh and the hamstring portion of the adductor magnus. It also indirectly supplies muscles of the leg and foot via its terminal branches. It has no direct sensory function but indirectly innervates the skin of the lateral leg, heel and the foot via its terminal branches.

The sciatic nerve can be divided into two individual nerves bundled together in the same connective tissue sheath, the tibial and common peroneal (fibular) parts. These two parts innervate different muscles and fully separate into two divisions at the termination of the sciatic nerve.

After its formation it passes out of the greater sciatic foramen below piriformis and enters the gluteal region. Although it passes through the gluteal region, it does not supply any muscles there.

It runs vertically down the midline of the posterior compartment of the thigh before terminating by bifurcating into the tibial and common peroneal (fibular) nerves at the apex of the popliteal fossa.

When administering an intramuscular (IM) injection in the gluteal region it is very important to consider the anatomical course of the sciatic nerve and the superior gluteal artery.

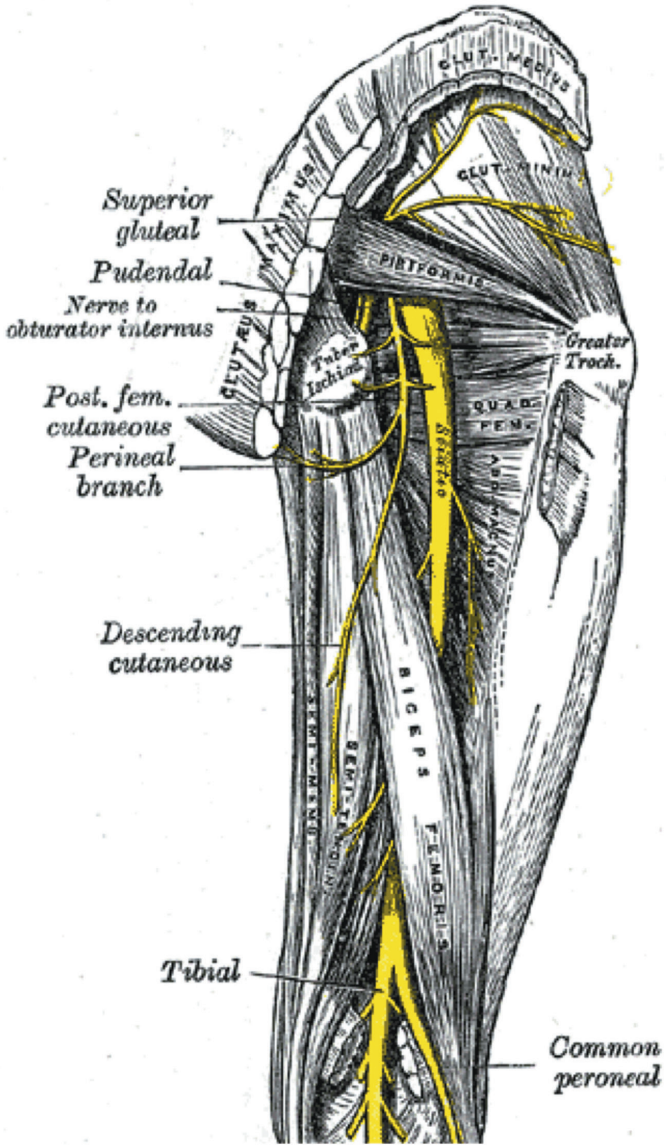

*Fig 55. The course of the sciatic nerve.**

The gluteal region can be divided into four quadrants using two lines:

- A vertical line descending from the highest point of the iliac crest
- A horizontal line passing through the anterior inferior iliac spine

The superior gluteal artery lies in the upper medial quadrant and the sciatic nerve passes through the lower medial and lower lateral quadrants. **Therefore the safest location to administer an IM injection in the gluteal region is the upper lateral quadrant.**

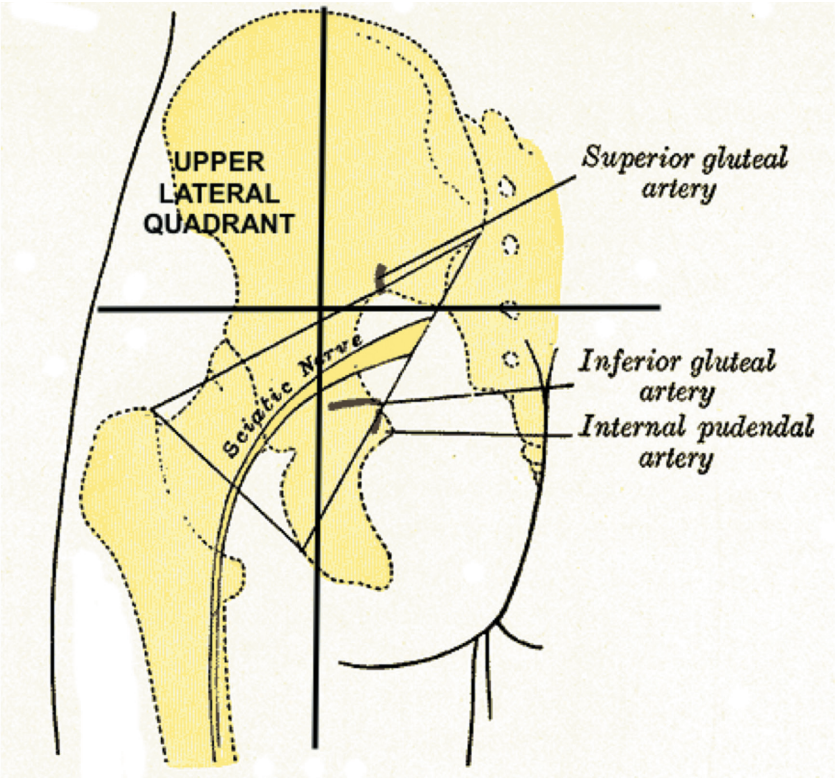

*Fig 56. The safe quadrant for IM injection is the upper lateral quadrant.**

The Common Peroneal Nerve

The common peroneal (fibular) nerve is the smaller terminal branch of the sciatic nerve, being about half the size of the tibial nerve. It supplies the muscles of the lateral and anterior compartments of the leg through its branches. It also innervates the skin of the upper lateral and lower posterolateral leg and the skin of the anterolateral leg and the dorsum of the foot through its branches. It arises at the bifurcation of the sciatic nerve at the apex of the popliteal fossa.

The common peroneal nerve is palpable as it winds superficially around the head of the fibula early in its course. It is vulnerable to damage at this point, particularly from fibular neck fractures. Damage to the common peroneal nerve can result in foot-drop.

6

Vertebral Levels

Vertebral levels are very commonly tested on in both undergraduate and postgraduate medical examinations. The most commonly encountered landmarks and structures found at the various vertebral levels are shown in the table below:

VERTEBRAL LEVEL	LANDMARKS & STRUCTURES
C1	Spinal root of accessory nerve crosses transverse process of atlas
C2	Superior cervical ganglion
C3	Body of hyoid bone
C4	Superior border of thyroid cartilage Bifurcation of common carotid arteries
C6	Cricoid cartilage Larynx ends and trachea begins Pharynx ends and oesophagus begins Inferior thyroid artery crosses carotid sheath Inferior laryngeal nerve enters larynx Vertebral artery enters transverse foramen of C6 Middle cervical ganglion
C7	Vertebra prominens Stellate ganglion Isthmus of thyroid gland Highest point of thoracic duct
T1	Sternoclavicular joint Highest point of lung apex
T2	Superior border of scapula
T2/3	Suprasternal notch

T3	Medial end of spine of scapula End of oblique fissure of lung posteriorly
T3/4	Top of arch of aorta
T3-4	Manubrium sterni
T4/5	Sternal angle (of Louis) Bifurcation of trachea Arch of aorta begins and ends Azygous vein enters superior vena cava
T5-8	Body of sternum
T6	Upper border of liver
T7	Inferior angle of the scapula
T8	Caval opening in the diaphragm Phrenic nerves traverse diaphragm
T8/9	Xiphisternal junction
T9	Xiphoid Superior epigastric vessels traverse diaphragm
T9-L3	Costal margin
T10	Oesphageal opening in the diaphragm
T12	Aortic opening in diaphragm Origin of the coeliac axis (lower border)
L1	Transpyloric plane of Addison Fundus of the gallbladder Hila of the kidneys First part of the duodenum Neck of the pancreas Origin of the superior mesenteric artery Origin of the portal vein Pylorus of the stomach Hilum of the spleen Cisterna chyli
L1/2	Spinal cord ends in adults Origin of renal arteries

L2	Subcostal plane Thoracic duct begins Azygous and hemiazygous veins begin Duodenojejunal flexure Ligament of Treitz (upper border)
L3	Origin of inferior mesenteric artery Spinal cord ends in infants
L3/4	Umbilicus
L4	Transtubercular plane Bifurcation of the aorta
L5	Formation of the inferior vena cava
S2	Sacral dimples Midpoint of sacro-iliac joints Posterior superior iliac spines Dural sac ends
S3	Pelvic colon ends and rectum begins Posterior inferior iliac spines
S4	Sacral hiatus Vertebral column ends

7

Surface Anatomy Map

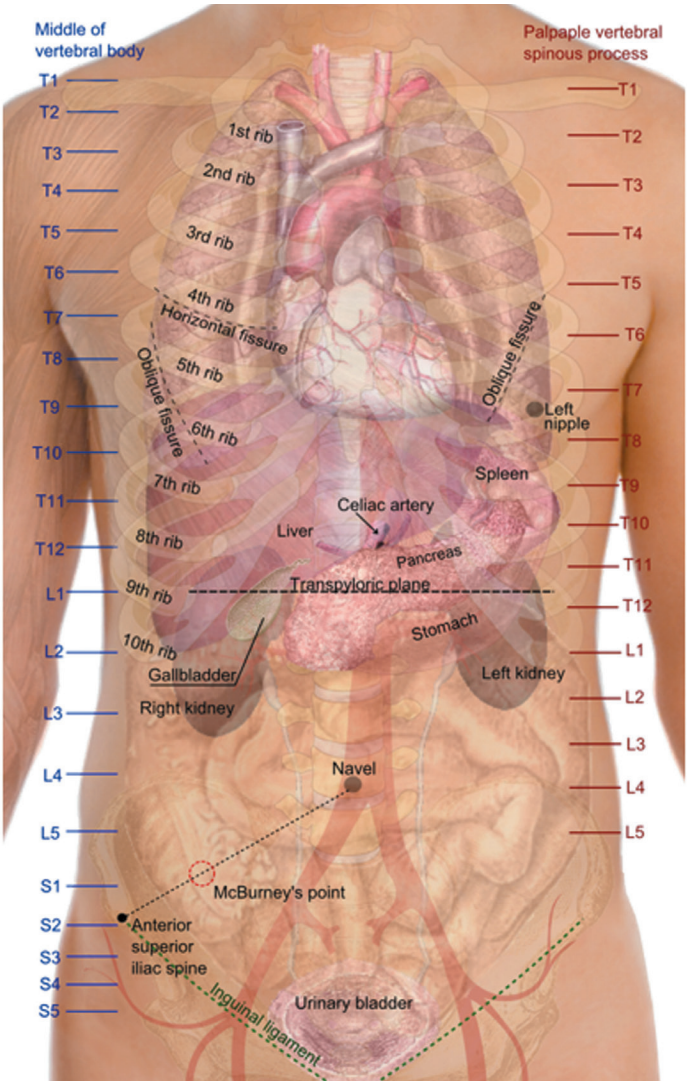

About the Author

Dr. Marc Barton qualified from Imperial College School of Medicine in 2001. Since that time he has worked in a variety of different medical specialities. He worked as a GP partner from 2006 until 2008 and more recently as a higher specialist trainee in Emergency Medicine.

He has gained a formidable reputation as an exam candidate and, in addition to passing a Bachelor of Science degree and Medical Finals as an undergraduate, he has also passed three postgraduate membership exams and two postgraduate diploma exams.

He has an active interest in medical education and a wealth of experience teaching both medical students and doctors.

In his private life he is a devoted husband and father of three children. He is also a lifelong martial artist and regularly teaches Jiu Jitsu in his spare time.

Information regarding images contained within this book

All images are copyrighted and owned by Medical Exam Prep Ltd, except those marked as follows:

* *PUBLIC DOMAIN IMAGE FROM 1918 EDITION OF GRAY'S ANATOMY OF THE HUMAN BODY*

§ *IMAGE USED ON LICENCE FROM SHUTTERSTOCK*

† *PUBLIC DOMAIN IMAGE FROM AN ATLAS OF ANATOMY BY JOHN CHARLES GRANT*

≠ *PUBLIC DOMAIN IMAGE FROM RAUBER'S LEHRBUCH DER ANATOMIE BY DR. FR. KOPSCH*